

7th Winfocus World Congress on Ultrasound in Emergency and Critical Care, 22–27 November 2011, New Delhi, India

ASSESSING DEHYDRATION IN CHILDREN WITH GASTROENTERITIS: A NOVEL USE OF BEDSIDE ULTRASOUND

S. Jones

Leeds Teaching Hospitals, Leeds, West Yorkshire, UK

Background: A novel ultrasonographic measurement of inferior vena cava (IVC) and aorta (Ao) diameter as a ratio (IVC/Ao) has been proposed to evaluate intravascular volume in children at risk of dehydration from e.g. gastroenteritis. This method is relatively quick and simple.

Objective: In a child presenting to the emergency department with gastroenteritis, can ultrasound objectively detect the presence of dehydration?

Patients and methods: This is a systematic review of the literature on the use of ultrasound (US) to assess dehydration in children.

Results: There are 5 prospective studies in children. The IVC/Ao ratio changed significantly with a fluid bolus in 4 of the 5 studies and was significantly different when compared with euvoletic controls. The ratio had a specificity of 56–100% and a sensitivity of 39–93% for the diagnosis of significant dehydration (at least 5% weight loss). In comparison, clinical assessment has a sensitivity of 73–78% and specificity of 43–51%. There was good inter-rater reliability with an interclass correlation coefficient (ICC) of 0.723 (Chen et al.) and a Pearson correlation coefficient of 0.76 (Levine et al.).

Conclusion: The IVC/Ao ratio change with intravascular volume is more sensitive and specific at assessing dehydration in children than clinical assessment. A ratio of <1 would suggest dehydration. In reality the differences measured are small and the practicalities of its use in an uncooperative child may limit its effectiveness. Reference values for IVC/Ao equivalence to percentage dehydration are needed.

References

- Chen L, Yunie K, Karen A, et al. Use of ultrasound measurement of the inferior vena cava diameter as an objective tool in the assessment of children with clinical dehydration. *Acad Emerg Med* 2007;14(10):841–5.
- Barata I, O'Donnell M.B, Kaban J, et al. Does inferior vena cava/aorta ratio correlate with fluid therapy in clinically dehydrated children? *Annals Emerg Med* 2009;54(3) S1.
- Levine AC, Shah SP, Umulisa I, et al. Ultrasound assessment of severe dehydration in children with diarrhea and vomiting. *Acad Emerg Med* 2010;17(10):1035–41.
- Barata I, Houdek LA, O'Donnell MB. Does ultrasonography measurement of inferior vena cava and inferior vena cava/aorta ratio correlate with fluid therapy in clinically dehydrated children with gastroenteritis? *Annals Emerg Med* 2010;56(3) S3.
- Chen L, Hsiao A, Langhan M, et al. Use of bedside ultrasound to assess degree of dehydration in children with gastroenteritis. *Acad Emerg Med* 2010; 17(10):1042–1047.

EMERGENCY DEPARTMENT BEDSIDE ULTRASOUND IN DIAGNOSIS OF ACUTE DUODENAL OBSTRUCTION DUE TO SUPERIOR MESENTERIC ARTERY SYNDROME IN PATIENT WITH ANOREXIA NERVOSA AND BULLYING

F. L. Resende, C. S. Brito, A. P. Antunes, P. H. S. Laia, E. O. Hansen, J. A. S. Pacheco, B. F. Belezia

Department of Emergency Medicine, Odilon Behrens Hospital, 50 Formiga Street, São Cristóvão, Belo Horizonte, MG, Brazil

Background: The Superior Mesenteric Artery Syndrome (SAMS), also known as Wilkie's syndrome is a rare entity (0.013–0.3%) caused by compression of the third portion of the duodenum by the superior mesenteric artery and abdominal aorta, resulting in acute or chronic obstruction of this segment. Sometimes a definitive diagnosis is difficult because it has similar symptoms to several gastrointestinal diseases.

In general, women are the most commonly affected and two-thirds of the patients are aged between 10 and 39 years old.

Several conditions predispose to the syndrome, with an impact on the aorto-mesenteric angle. They can be summarized in three categories: severe weight loss in catabolic states, external causes and intra-abdominal compression or mesenteric tension.

Objective: Reporting a case that emphasizes the usefulness of bedside ultrasound in diagnosing acute duodenal obstruction due to SAMS.

Case report: A 17-year-old teenager, female, presented to Emergency Department (ED) with epigastric pain, progressive dysphagia and frequent vomiting after meals in the last 30 days. She was having psychological counseling by sudden and significant reduction of food intake after negative comments from classmates about her weight. ED bedside ultrasound showed a giant gastric stasis and duodenal dilation up to the Superior Mesenteric Artery. There were no signs of small bowel or colonic obstruction on ultrasound examination. REED, computed tomography and endoscopy confirmed these findings. We decided to submit the patient to conservative treatment, parenteral nutritional support and psychological counseling with resolution of the case.

Conclusion: The bedside ultrasound can raise the suspicion of duodenal obstruction. The Superior Mesenteric Artery Syndrome should be considered in the current context of eating disorders and behaviors of social aggression such as bullying.

References

- Neri SS, Mondati E. Ultrasound imaging in diagnosis of superior mesenteric artery syndrome. *J Intern Med* 2005;257(4):346–51.
- Lippl F, et al. Superior mesenteric artery syndrome: diagnosis and treatment from the gastroenterologist's view. *J Gastroenterol.* 2002;37:640–3.

EFFECTIVENESS OF SIMULATION BASED ULTRASOUND EDUCATION IN INTERNAL MEDICINE RESIDENTS: IMPROVING THEIR KNOWLEDGE, ATTITUDE AND SKILLS WITH ULTRASOUND USE

A. Bhagra

Department of Medicine, Mayo Clinic, Rochester, MN, USA

Background: Formal ultrasound (U/S) training is not universally included in medical school or Internal Medicine residency training in the United States. However, new standards of care recommend that numerous invasive procedures such as central line placement and thoracentesis be performed with U/S guidance. U/S is also emerging as an important physical examination tool.

Objective: To measure effectiveness of an innovative ultrasound curriculum to improve Internal Medicine interns' knowledge of ultrasound, skills with its use, and attitudes towards future use of ultrasound during residency and in future clinical careers.

Patients and methods: A formal U/S didactic and "hands-on" curriculum was incorporated into Internal Medicine interns' orientation. The interns completed pre- and post-workshop questionnaires, image identifications, and skills assessments to evaluate the efficacy of the workshop to improve their knowledge of, skill with, and attitude towards use of U/S. Paired *t* tests and Cochran-Mantel-Haenszel tests were used to assess effects of the training workshop.

Results: Of the 67 interns, 15 (22.4%) had received some prior U/S training and 36 (53.7%) had used U/S for procedures, most commonly for central venous access (75.0%). Following the didactic portion, there was significant improvement in correct identification of air (32–98%) and fluid (72–100%). The ability to identify ascites improved from 10 to 58%; kidney from 43 to 97%; thyroid from 31 to 97%; and pleural effusion from 6 to 69%. The percent of interns able to set appropriate gain for optimal image acquisition improved from 42 to 94%, and depth from 30 to 88%. The number of interns able to locate the internal jugular vein and demonstrate its compressibility improved from 61 to 94%. The number of those who obtained an image in under 2 min rose from 64 to 88% and mean (SD) image acquisition time decreased from 72 (28) to 52 (26) s. Reported confidence in ability to use U/S, belief that its use would decrease adverse events with thoracentesis and central line placement, and likelihood of using U/S guidance during invasive procedures also significantly improved following this simulation based workshop (all *p* < 0.001).

Conclusion: Simulation based U/S training is effective in improving Internal Medicine interns' knowledge, skills, and attitude towards the use of U/S for invasive procedures.

USE OF ULTRASONOGRAPHY IN RAPID DIAGNOSIS OF RESPIRATORY DISTRESS IN EMERGENCY DEPARTMENT

M. Piyush, U. Surjya, S. Wahaba, R. K. A. Singh, K. Devender, E. Waleed
Presenting Author: M. Piyush

Al Jahra Hospital Kuwait

Background: Many patients presenting with respiratory distress have challenging diagnosis. The majority of respiratory distresses are managed addressing both a cardiac or respiratory origin, without reaching a definitive diagnosis. Ultrasonography is being increasingly used for rapid bedside diagnosis in varieties of emergency situation.

Objective: Objective of this study is to assess the feasibility and accuracy of bedside lung ultrasound to differentiate respiratory distress either of cardiac or primary respiratory origin based on some specific sonographic pleural and pulmonary signs and to find out correlation with other routine diagnostic tools.

Materials and methods: This is a prospective cohort study on 40 consecutive patients aged more than 60 years presenting with acute respiratory distress, where anesthetist was on-call for resuscitation and respiratory support. Bedside sonographic imaging of chest was obtained by using curvilinear probe and scanning 8 different chest areas. Based on the finding of A-lines and B-lines, patients were categorized into primary respiratory and cardiac origin of respiratory failure. Conventional diagnostic tools, such as chest radiography including CT scan in doubtful cases, natriuretic peptides and, Procalcitonin, were also used.

All data were collected and analyzed using SPSS 2010. Quantitative data were presented either as percentage, mean with SD and analyzed using Chi-square test, student *t* test. A *P* value of 0.05 was considered as statistically significant.

Results: Our study indicated that primary cardiac origin of respiratory distress, such as acute pulmonary edema, can be diagnosed with almost 95% sensitivity and 92% specificity with lung ultrasound, while the respiratory distress of primary respiratory origin (COPD, asthma, pneumonia) is diagnosed with 80% sensitivity and 64% specificity.

Conclusion: Bedside ultrasonography of the chest is a non-invasive method that can be performed at any time and any place and can accurately diagnose and differentiate respiratory distress of cardiac or respiratory origin.

References

- Lichtenstein D, Biderman P, Meziere G, Gepner A. The "sinusogram", a real-time ultrasound sign of maxillary sinusitis. *Intensive Care Med.* 1998;24:1057–1061.
- Lichtenstein D, Goldstein I, Mourgeon E, Cluzel P, Grenier P, Rouby JJ. Comparative diagnostic performances of auscultation, chest radiography, and lung ultrasonography in acute respiratory distress syndrome. *Anesthesiology* 2004;100:9–15.
- Greenbaum DM, Marschall KE. The value of routine daily chest X-rays in intubated patients in the medical intensive care unit. *Crit Care Med.* 1982;10:29–30.
- Bekemeyer WB, Crapo RO, Calhoun S, Cannon CY, Clayton PD. Efficacy of chest radiography in a respiratory intensive care unit. A prospective study. *Chest* 1985;88:691–696.
- Rouby JJ, Puybasset L, Cluzel P, Richecoeur J, Lu Q, Grenier P. Regional distribution of gas and tissue in acute respiratory distress syndrome. II. Physiological correlations and definition of an ARDS Severity Score. CT Scan ARDS Study Group. *Intensive Care Med.* 2000;26:1046–1056.
- Mayo JR, Aldrich J, Muller NL. Radiation exposure at chest CT: a statement of the Fleischner Society. *Radiology.* 2003;228:15–21.
- Beckmann U, Gillies DM, Berenholtz SM, Wu AW, Pronovost P. Incidents relating to the intra-hospital transfer of critically ill patients. An analysis of the reports submitted to the Australian Incident Monitoring Study in Intensive Care. *Intensive Care Med.* 2004;30:1579–1585.

THE USE OF BEDSIDE SUBCOSTAL ULTRASOUND IN CARDIAC ARREST DUE TO MASSIVE PULMONARY EMBOLISM: A GUIDE TO THROMBOLYTIC THERAPY

F. L. Resende, C. S. Brito, E. O. Hansen, P. C. Diniz, B. F. Belezia

Department of Emergency Medicine, Odilon Behrens Hospital, 50 Formiga Street, São Cristovão, Belo Horizonte, MG, Brazil

Background: Identifying the underlying cause of cardiac arrest (CA) represents a great challenge in clinical practice. Bedside ultrasound has been reported as a useful tool in such cases.

Objective: We report a case that shows the usefulness of bedside ultrasound in CA due to massive pulmonary embolism (PE).

Case report: A 38-year-old woman presented to the Emergency Room with a history of syncope 1 h prior to her arrival. The patient was obese, nonsmoker and was taking oral contraceptives. No other known risk factors for PE. Physical exam: obnubilated, diaphoretic, bad capillary refill, undetectable blood pressure, 130 bpm, lactic acidosis, dyspnea, and hypoxemia. Despite initial volemic resuscitation and ventilatory support, she had a CA in pulseless electrical activity (PEA) followed by resumption of spontaneous circulation (ROSC) after 6 min of cardiopulmonary resuscitation (CPR). She did not sustain the rhythm, thus CPRs were performed. Bedside ultrasound with subcostal curvilinear transducer (3–5 MHz) used in intervals of ROSC revealed dilatation of right heart chambers and inferior vena cava. Because of the high suspicion of massive PE, we administered recombinant tissue plasminogen activator (r-TPA).

She assumed spontaneous circulation about 5 min after r-TPA infusion, totaling 70 min since the first CPR. 12-lead ECG showed an S1-Q3-T3 pattern. A second level echocardiogram confirmed compatibility with PE.

Intensive care during 30 days was then applied with complete recovery. Control echocardiogram on day 45 evidenced improvement of right ventricular function and stable pulmonary hypertension. The patient was discharged with total functional independence.

Conclusion: Identifying the cause of PEA or asystole is important as the underlying condition is what guides appropriate therapy. Ultrasound is a diagnostic tool with the potential to guide management in real time, at the bedside, bringing diagnostic clarity to clinical decision-making and better outcomes.

References

- Hernandez C, et al. Cardiac arrest ultrasound exam—a better approach to managing patients in primary non-arrhythmogenic cardiac arrest. *Resuscitation*. 2008;76:198–206.

RESPIRATORY VARIATION OF THE VELOCITY TIME INTEGRAL OF THE FLOW THROUGH AORTIC VALVE AND SONOGRAPHIC INFERIOR VENA CAVA DIAMETER AS A GUIDE TO MANAGE FLUID THERAPY IN SEPTIC PATIENT

ECHO VTI AND ULTRASONOGRAPHIC IVC DIAMETER'S RESPIRATORY VARIATION AS A GUIDE MANAGE FLUID THERAPY IN SEPTIC PATIENT

M. Piyush, U. Surjya, T. Salah, M. A. Shamsah, E. Waleed, W. Serif,
Presenting Author: M. Piyush
Corresponding Author: M. A. Shamsah

Ministry of Health Kuwait, Al Jahra Hospital,
Department of Critical care Medicine

Background: Fluid resuscitation is one of the most critical interventions during initial phase of management in sepsis. Traditional approach for fluid management relied on invasive lines (central venous or pulmonary artery catheters) for volume estimation and response to therapy, which are complicated techniques and sometimes infeasible or contraindicated due to anatomical difficulty and coagulopathy. We describe a simple non-invasive method that can be easily applied for estimation of fluid status and response to fluid therapy.

Patients and methods: We enrolled 10 patients with severe sepsis and obvious coagulopathy for our preliminary study on initial fluid resuscitation. Method used in these patients were both inferior vena cava (IVC) assessment and transthoracic echocardiography guided velocity time integral (VTI) flow through aortic root, which were used to assess volume status and response to fluid loading. Lactate reversal of 10% per hour was considered as equivalent to mixed venous oxygen saturation (SVO₂) of 70%. Interestingly all patients were managed with non-invasive ventilation method (BiPAP).

Inferior Vena cava Assessment: transabdominal approach with standard size ultrasound probe was used for both 2D and M mode. First of all aorta was identified by placing the probe in longitudinal plane, midline in epigastric region just below the sternum. Once aortic pulsation was confirmed, probe was moved to right to visualize IVC. IVC diameter as during inspiration and expiration was noted at 2 cm beyond the hepatic vein. Caval index was calculated as (maximum diameter–minimum diameter) × 100/maximum diameter. Maximum IVC diameter of more than 2 cm with caval index less than 30% was considered as CVP value of 10 cmH₂O or more and caval index of more than 50% irrespective of diameter was consider as CVP of less than 5 cmH₂O, respectively.

Echo VTI: Long axis 5 chambers view with M mode was used to assess the flow through the aortic valve. Peak velocity of flow (V_{peak}) through the aortic valve was used as VTI value. Percentage of change in VTI value was calculated as—maximum VTI value (V_{peak} max) – minimum VTI (V_{peak} min)/mean VTI or V_{peak} mean. More than 12% change in VTI value with respiration was consider as fluid responsive (as suggested by Feissel et al.) and fluid resuscitation was continued till the VTI variation was less than 12%.

Discussion: Use of IVC diameter assessment and its variations with respiration is a relatively new and simple method for assessing fluid volume status and the response to fluid therapy. Barbier et al. used IVC diameter as a measure of fluid responsiveness in septic patients on positive pressure ventilation in a retrospective study and found that more than 18% variation in IVC diameter with respiration was strongly correlated with preload sensitivity with 90% sensitivity and specificity. Feissel et al. also used variation of IVC diameter during respiration as a guide to fluid therapy in mechanically ventilated septic patients and found that IVC diameter variation of more than 12% allowed identification of responders with positive and negative predictive values of 93 and 92%, respectively. Recently Nagdev et al. conducted a study to determine correlation between ultrasonographic IVC index and CVP in an emergency setting where CVP lines were inserted for resuscitation. They compared the CVP value with the caval index and found that the correlation between caval index and central venous pressure was –0.74. The sensitivity of caval index greater than or equal to 50% to predict a central venous pressure less than 8 mmHg was 91%, the specificity was 94%. Sonographic IVC study has some limitations. In patients with increased intra-abdominal pressure the measurement of IVC diameter may not reliably correlate with the volume status and application of PEEP may overestimate the value. Technically IVC assessment may be challenging in patients with distended abdomen, ascites or obesity.

Echocardiography is a fantastic noninvasive tool, which can directly visualize the heart and assess cardiac function. VTI measures flow in unit time across aortic valve and variation with respiratory cycle. It is a dynamic measurement and is more useful to determine the response to fluid infusion in a dynamic way. Flow dependent value like VTI will definitely be more accurate than static pressure value like CVP as per some of the recent study. Feissel et al. has demonstrated in a prospective clinical trial that echocardiographic VTI evaluation during a respiratory cycle accurately predicts fluid response in septic patients on mechanical ventilation, a Δ VTI or Δ Vpeak threshold value of 12% allowed discrimination between responders and non-responders with a sensitivity of 100% and a specificity of 89%. In an animal study, Slama et al. showed that progressive blood loss was closely related to increased respiratory variation of aortic blood flow. Historically, transesophageal echocardiography (TEE) has been favored over the transthoracic technique (TTE) in critically ill patients. This was largely because of the challenge in obtaining images during respiration. In awake spontaneously breathing patients, such as our cases, the use of TTE is very difficult. TTE allowed also evaluation of cardiac contractility by using the short axis parasternal view of the left ventricle. This also helped in decision making of inotropic versus vasopressor agent requirements.

Main Limitation of VTI study is that it is technically a more complex method than ultrasonography of IVC. Moreover, it may not be possible to apply the method to patients with severe obesity or pulmonary emphysema. Measurements of VTI require advanced training in cardiac ultrasonography. The operator must be skilled in Doppler applications including knowledge of angle and position effect on Doppler measurements, while cardiac translation movement artifact must be recognized.

Conclusion: Early use of non-invasive techniques like ultrasonography IVC and echo VTI look to be quite feasible option that may be more safe and reliable during early goal directed therapy. However, randomized control trial with larger sample size is definitely warranted to place these non-invasive methods as the techniques of first choice during early resuscitation phase in sepsis.

References

- Dellinger RP, Levy MM, Carlet JM, et al. Surviving Sepsis Campaign guidelines for management of severe sepsis and septic shock. *Crit Care Med*. 2008;36(1).
- Ely EW, Baker AM, Dunagan DP, et al. Effect on the duration of mechanical ventilation of identifying patients capable of breathing spontaneously. *NEJM*. 1996;335:1864–1869.
- Nagdev AD, Merchant RC, Tirado-Gonzalez A, et al. Emergency department bedside ultrasonographic measurement of the caval index for noninvasive determination of low central venous pressure. *Ann Emerg Med*. 2010;55(3):290–5.
- Barbier C, Loubières Y, Schmit C et al. Respiratory changes in inferior vena cava diameter are helpful in predicting fluid responsiveness in ventilated septic patients. *Intensive Care Med*. 2004;30(9):1740–6.
- Feissel M, Michard F, Faller JP et al. The respiratory variation in inferior vena cava diameter as a guide to fluid therapy. *Intensive Care Med*. 2004;30(9):1834–7.
- Blehar DJ, Dickman E, Gaspari R. Identification of congestive heart failure via respiratory variation of inferior vena cava diameter. *Am J Emerg Med*. 2009;27(1):71–5.
- Wallace DJ, Allison M, Stone MB. Inferior vena cava percentage collapse during respiration is affected by the sampling location: an ultrasound study in healthy volunteers. *Acad Emerg Med*. 2010;17(1):96–9 (Epub 2009 Dec 9).
- Thiel SW, Kollef MH, Isakow W. Non-invasive stroke volume measurement and passive leg raising predict volume responsiveness in medical ICU patients: an observational cohort study. *Crit Care*. 2009;13(4):R111
- Feissel M, Michard F, Mangin I, Ruyer O, Faller JP, Teboul L. Respiratory changes in aortic blood velocity as an indicator of fluid responsiveness in ventilated patients with septic shock. *Chest*. 2001;119:867–73.
- Lamia B, Ochagavia A, Monnet X, Chemla D, Richard C, Teboul JL. Echocardiographic prediction of volume responsiveness in critically ill patients with spontaneously breathing activity. *Intensive Care Med*. 2007;33(7):1125–32.
- Slama M, Masson H, Teboul JL et al. Respiratory variations of aortic VTI: a new index of hypovolemia and fluid responsiveness. *Am J Emerg Med*. 2009;27(1)
- Charron C, Caille V, Jardin F, Vieillard-Baron A. Echocardiographic measurement of fluid responsiveness. *Curr Opin Crit Care*. 2006;12(3):249–54
- Jue J, Chung W, Schiller N.B. Does inferior vena cava size predict right atrial pressures in patients receiving mechanical ventilation? *J Am Soc Echocardiogr*. 1992;5:613–619.
- Slama M, Masson H, Teboul JL, et al. Respiratory variations of aortic VTI: a new index of hypovolemia and fluid responsiveness. *Am J Physiol Heart Circ Physiol*. 2002;283:1729–1733.
- Orme R.M.L. E, Oram M. P, McKinsty C. E. Impact of echocardiography on patient management in the intensive care unit: an audit of district general hospital practice. *Br J Anaesth*. 2009;102(3):340–4.
- Kitakule MM, Mayo P. Use of ultrasound to assess fluid responsiveness in the intensive care unit. *Open Crit Care Med J*. 2010;3:33–37.
- Jonathan E. Sevransky, Mitchell M. Levy, John J. Marini. Mechanical ventilation in sepsis-induced acute lung injury/acute respiratory distress syndrome: an evidence-based review. *Crit Care Med*. 2004;32[Suppl.]:S548–S553.
- Rivers E, Nguyen B, Havstad S, et al. Early Goal-Directed Therapy Collaborative Group. Early goal-directed therapy in the treatment of severe sepsis and septic shock. *N Engl J Med*. 2001;345(19):1368–1377.
- Carlbom DJ, Rubenfeld GD. Barriers to implementing protocol-based sepsis resuscitation in the emergency department—results of a national survey. *Crit Care Med*. 2007;35(11):2525–2532.
- Arnold RC, Shapiro NI, Jones AE et al. Multi-center study of early lactate clearance as a determinant of survival in patients with presumed sepsis. *Shock*. 2009;32(1):35–39.
- Nguyen HB, Rivers EP, Knoblich BP, et al. Early lactate clearance is associated with improved outcome in severe sepsis and septic shock. *Crit Care Med*. 2004;32(8):1637–1642.
- Jones AE, Shapiro NI, Trzeciak S, Arnold RC, Heather A. Claremont, Jeffrey A. Kline. Lactate clearance vs central venous oxygen saturation as goals of early sepsis therapy: a randomized clinical trial. Emergency Medicine Shock Research Network (EMShockNet) Investigators. *JAMA*. 2010;303(8):739–746.

ULTRASOUND DIAGNOSIS OF MYOPERICARDITIS IN A YOUNG PATIENT WITH UNKNOWN HIV INFECTION IN THE EMERGENCY DEPARTMENT

M. Frameglia, E. Frongia, L. Adami, A. Zocca, B. Genco, V. Parise, G. Battizocco

Emergency Department, Orlandi Hospital, Bussolengo, Verona, Italy

Background: Chest discomfort is a common challenge in the Emergency Department. Echography examination can be very helpful

in making a correct diagnosis in a short time, as is shown in this clinical case.

Case report: A young man, 34 years old, came recently to our Emergency department complaining of chest pain lasting from 1 week. Intermittent fever was also present, sometimes with shivering. The pain was depicted as subcontinuous, with exacerbations during exertion. The patient's respiratory and hemodynamic status was not compromised. The ECG showed non-specific changes of the ventricular repolarization. At the physical examination a third sound and subtle pericardial rubs were present.

A "fast" echographic examination did not reveal alterations in the lungs; the left ventricle was slightly dilated, with a diffuse parietal hypokinesis and a global ejection fraction of 0.40. A mild pericardial effusion, without signs of cardiac tamponade, was also present.

The blood tests demonstrated mild anemia (Hgb 10 g/L) with leucopenia (2.22 giga/L), neutropenia (1.2 giga/L) and lymphocytopenia (0.4 giga/L). C-reactive protein was 23.8 mg/L. A substantial rise in the value of Troponin was also evident (8.640 µg/L with cut-off 0.070 µg/L).

An operative diagnosis of myocarditis with pericarditis was made and the patient was admitted to the cardiology department. An infection of HIV was then diagnosed. Definitive diagnosis and treatment are under way at the moment of this communication.

Conclusion: In conclusion echography was extremely useful in the management of this patient in the Emergency department to orient towards the correct diagnosis. A fast echographic examination made in emergency room made easier and faster the evaluation of chest discomfort of our patient.

RAPID ULTRASOUND FOR SHOCK AND HYPOTENSION—RUSH—IN MASSIVE HEMOTHORAX DUE TO PERFORATED ATHEROSCLEROTIC AORTIC ULCER WITH THORACIC AND ABDOMINAL DISSECTION

F. L. Resende, C. S. Brito, J. B. R. Júnior, E. O. Hansen, B. F. Belezia

Department of Emergency Medicine, Odilon Behrens Hospital, 50 Formiga Street, São Cristovão, Belo Horizonte, MG, Brazil

Background: The RUSH exam was designed to be rapid and easy to perform with the ultrasound machines found in emergency departments (ED). The components of the exam are heart, inferior vena cava (IVC), Morison's/FAST abdominal views with thoracic windows, aorta, and pneumothorax scanning.

Objective: Report a case emphasizing the benefits of RUSH in a massive hemothorax case due to perforated atherosclerotic aortic ulcer with thoracic and abdominal dissection.

Case report: A 62-year-old male presented to the emergency room with a sudden chest pain, diaphoresis, cyanosis, and cold extremities. He was with mental confusion, undetectable blood pressure, and lactic acidosis. The patient had a past medical history of abdominal aortic aneurysm.

Electrocardiogram was not significant and chest X-ray showed a "white lung" on the right. The RUSH exam was performed with a curvilinear transducer (3–5 MHz) and revealed the following findings: hyperdynamic left ventricle, collapsed left ventricle and IVC, massive right pleural effusion, pulmonary consolidation, and a suprailiac abdominal aorta with a thrombosis inside the lumen.

Volemic resuscitation was began and the patient was intubated for ventilatory support. Ultrasound guided thoracocentesis was performed

and showed blood on aspiration. Therefore, a chest tube was inserted and packed red cells units were administered.

Computed tomography showed a descending thoracic aortic dissection down to the upper abdominal aorta. The patient was transferred to an endovascular facility and an endoprosthesis was inserted 24 h after initial diagnosis. After several weeks of intensive care, he was sent home.

Conclusion: The RUSH exam provides a sequenced approach to ultrasound in the medical shock patients without obvious etiology and can reduce the number of conditions that needs to be ruled out. It also indicates the best approach, as well as a quicker time to final diagnosis, even in rare disease presentation like in our case.

References

Lichtenstein DA, Meziere GA. Relevance of lung ultrasound in the diagnosis of acute respiratory failure: The BLUE protocol. *Chest*. 2008;134:117–125.

WHAT IS THE OPTIMAL INSERTION ANGLE BETWEEN THE SKIN AND NEEDLE IN ULTRASOUND-GUIDED INTERNAL JUGULAR VEIN CATHETERIZATION?

S. W. Kim, H. M. Jeon, J. Jeon, J. W. Ahn, Y. R. Ha

Dept. of Emergency Medicine, Bundang Jeseang Hospital,
Dept. of Emergency Medicine, Chungnam University,
Dept. of Emergency Medicine, Ajou University

Background: It has been reported that internal jugular vein (IJV) diameter could be changed along the central venous pressure (CVP).

Objective: We tried to identify whether the optimal insertion angle between the skin and needle in ultrasound-guided IJV catheterization would be changed depending on the patient's CVP.

Patients and methods: Using the 3.5-cm long linear probe, we measured the distance from the skin to IJV's outer and inner surface on the longitudinal scan's midline in supine-positioned patients who were indicated for central venous catheterization regardless of suspected diagnoses in emergency department. We calculated the angle between skin and the imaginary line from the puncture site to the IJV's internal center on screen's midline (defined as optimal angle which is considered as the safest approach) on the longitudinal scan. We measured patients' CVP after catheterization. We divided the patients into 3 groups based on the CVP (low CVP <5 cmH₂O, ≤middle CVP ≤10 cmH₂O, and high CVP >10 cmH₂O) and compared their mean AP diameters and optimal angles using ANOVA statistics.

Results: A total of 56 patients were enrolled. 36 were women (64.3%). Mean age, AP diameter, and optimal angle were 62.9 ± 16.8 ys, 1.01 ± 0.40 cm and 29.1 ± 5.01 degrees, respectively. 13, 32, and 11 patients belonged to low, middle, and high CVP group. Normality was acquired in AP diameter and optimal angle by Shapiro–Wilk test ($p > 0.05$). The mean AP diameter of low CVP group was significantly lower than middle and high CVP groups (0.68 ± 0.30, 1.06 ± 0.31, and 1.23 ± 0.49 cm, respectively, $p < 0.05$). There was no significant difference among 3 groups' mean optimal angles (28.1 ± 6.1, 30.1 ± 4.5, and 28.0 ± 5.0 degree respectively).

Conclusion: The optimal angle between the skin and needle in ultrasound-guided IJV catheterization is not changed as about 30 degree regardless of CVP even though IJV's diameter is altered in proportion to the CVP.

BEDSIDE ULTRASOUND IN EXTENSIVE DEEP CERVICAL INFECTION: LUDWIG'S ANGINA WITH AIRWAY COMPROMISE

F. L. Resende, C. S. Brito, L. B. Rodrigues, A. P. Antunes, E. O. Hansen, B. F. Belezia

Department of Emergency Medicine, Odilon Behrens Hospital, 50 Formiga Street, São Cristovão, Belo Horizonte, MG, Brazil

Background: The Ludwig's angina is a potential fatal deep cervical infection when it compromises the airway. Ultrasound is a diagnostic tool with increasing applications and use in emergency situations. Computed tomography (CT) is the imaging modality of choice for the diagnosis of deep neck space infections.

Objective: Reporting a case that emphasizes the benefits of bedside ultrasound in Ludwig's angina.

Case report: A 35-year-old male was admitted to the emergency department with submandibular and cervical pain and swelling for 6 days. He had a past medical history of trauma 2 months before. He was clinically stable and had fever, lockjaw, dysphagia, and purulent fluid from the lower left second molar tooth with ipsilateral submandibular and cervical swelling.

A CT study revealed deep fluid collection with gas. Antibiotic was begun, with initial improvement. After 4 days, he experienced again fever, worsening of cervical swelling and pain, and became dyspneic. Bedside ultrasound with linear transducer (7–9 MHz) showed the following findings: deep fluid collection (below the fascia) in left submandibular, left and right anterior cervical, and pre-tracheal spaces with gas inside. It was difficult to visualize the airway because of the air. Because of the high probability of a difficult surgical airway, cricothyroidotomy point was marked. Fiberscope-guided intubation, drainage of the abscess guided by ultrasound, and tracheostomy were then performed.

On the fifth postoperative day, the patient still presented submandibular and submental swelling, fever, and leukocytosis. Bedside ultrasound revealed collection in these areas. CT evidenced the same findings. Ultrasound guided drainage was then performed in the surgical block. We then obtained a good evolution, with decannulation and hospital discharge.

Conclusion: Bedside ultrasound is an important tool in emergency department with potential application in the diagnosis and for guiding treatment of deep cervical infections like Ludwig's angina.

References

Gaspari RJ. Bedside ultrasound of the soft tissue of the face: a case of early Ludwig's angina. *J Emerg Med* 2006;3:287–91.

SUBCUTANEOUS PAINFUL ABDOMINAL MASS WITH SPONTANEOUS BLEEDING 5 YEARS AFTER CESAREAN SECTION

T. Kubota, T. Yamashiro, A. Gabe, Y. Kang, Y. Ishida, N. Taira, T. Uehara

Department of General Surgery Okinawa Hokubu Hospital Nago, Japan

Background: In general, ultrasound is greatly useful for the diagnosis of subcutaneous mass.

Objective: We present a rare case of subcutaneous mass with spontaneous bleeding.

Patients and methods: The patient was 34 years-old female. She came to our emergency department complaining of lower abdominal pain. After a first physical examination, we detected signs of active subcutaneous bleeding on her left lower abdomen. On the site, a 3–4 cm sized palpable mass was present. It was hard and fixed with the abdominal wall. We studied the features of the mass by using ultrasound. The examination showed a hypoechoic mass at the subcutaneous level over the fascia. Its surface margin was blurred and vascularity was increased. The image closely resembled a “breast cancer”. She had been a healthy woman without any seriously illness except for a history of cesarean operation.

Results: The patient was submitted to surgery in 1 week. Under general anesthesia, wide local excision including skin and fascia was performed. Care was taken to make margin free resection. When the specimen was cut, old blood flowed out from the fibrosis. Pathological study showed presence of endometrial tissue.

Conclusion: Some authors previously published cases of abdominal wall endometrioma, in patients who had a history of prior cesarean section. In these cases, sonography showed hypoechoic, solid, vascular mass with some cystic changes. Emphasis should be placed on the history of cesarean section and some ultrasound findings to diagnose abdominal wall endometrioma.

References

- Hensen JH, et al. Abdominal wall endometriosis: clinical presentation and imaging features with emphasis on sonography. *Am J Roentgenol*. 2006;186:616–620.
- Accetta I, et al. Abdominal wall endometrioma. *Rev Col Bras Cir*. 2011;38:41–44.
- Blanco RG, et al. Abdominal wall endometriomas. *Am J Surg*. 2003;185:596–598.

ULTRASOUND ASSESSMENT OF INTERNAL JUGULAR VEIN DIAMETER: A VISUAL MANOMETER FOR MEASURING CENTRAL VENOUS PRESSURE

P. Sowjanya, T. Appireddy

Emergency Medicine, Mahatma Gandhi Super specialties Hospital, Narsaraopet, Guntur District, Andhra Pradesh

Background: Central venous pressure (CVP) monitoring is a crucial modality in critically ill patients to assess the fluid status. The traditional method for measuring CVP uses a central vein catheter, and therefore is an invasive and time-consuming procedure. A non-invasive CVP measurement is desirable for the emergency physicians facing with critically ill patients. The changes in CVP are directly proportional to the volume changes of the vessels. The diameter of the veins varies according to the pressure and the volume of blood flow.

Objective: To assess the reliability of ultrasound guided internal jugular vein (IJV) diameter in measuring CVP in critically ill patients.

Patients and methods: This is a prospective comparative analytical study done in our hospital from November 2009 to July 2010. We included in the study patients older than 18 years old requiring central line for various purposes. Patients with history of cardiac disease, liver failure and coagulation abnormalities were excluded. Ultrasound was performed by using a linear probe placed transversely 2 cm above the clavicle. The patients were kept in the supine position and the head of the patient in the midline. IJV was identified and the anterior-posterior diameter of the vein was measured using the cursor. A triple lumen catheter was then inserted and CVP was measured by a standardized traditional fashion. The measured IJV diameters were

compared with the CVP measurements. The correlation between the ultrasound guided IJV anterior-posterior diameter and the CVP values were documented and data analyzed.

Results: Fifty patients (41 male) were included in the study, while 9 patients were excluded. The correlation coefficient between the mean IJV diameter and the CVP score is 0.969 with a P value of 0.01.

Conclusion: Main conclusion of our study is that the ultrasound assessed IJV diameter has a good positive correlation with the central venous pressure.

FETAL ECHOCARDIOGRAPHY OF SEVERELY OBSTRUCTED TOTAL ANOMALOUS PULMONARY VENOUS CONNECTION RELATED TO SINGLE VENTRICLE; TWO DEATH CASES

Y. Yoshikane¹, T. Yoshizato², J. Hashimoto¹, M. Ueda¹, N. Fusazaki³, S. Hirose¹

¹Department of Pediatrics, Faculty of Medicine, Fukuoka University, Fukuoka, Japan

²Center for Maternal, Fetal and Neonatal Medicine, Fukuoka University Hospital, Fukuoka, Japan

³Department of Neonatal Cardiology, Fukuoka Children's Hospital, Fukuoka, Japan

Introduction: The majority of patients with functional single ventricle (SV) and total anomalous pulmonary venous connection (TAPVC) have heterotaxy syndrome with right atrial isomerism (RAI). When TAPVC is complicated by pulmonary venous obstruction (PVO), the patient's condition can deteriorate rapidly after birth. Appropriate prenatal assessment of PVO may avoid early death. We experienced two cases of TAPVC with extremely severe PVO related to SV and assessed their fetal echocardiogram findings retrospectively.

Case 1: The case 1 refers to a boy who was born at 39 weeks gestation. He had a generalized severe cyanosis from birth. He died 6 h after birth. At the maternal first visit, 38 weeks of gestation, a fetal echocardiogram showed echo free space, which supposedly is common PV chamber. However, there was no blood-flow signal in the space.

Case 2: The case 2 refers to a boy who was born at 37 weeks gestation. He also had a generalized severe cyanosis from birth. He underwent a TAPVC repair at 2 days old. However, he died because of exacerbation of PVO at 48 days old. At 20 weeks of gestation, echo free space and PV flow was unclear in the fetal echocardiogram. At 33 weeks of gestation, a venous return into atrium was visualized in color-Doppler. This caused an underestimation of the severity of PVO.

Conclusion: Severe PVO related to SV and TAPVC shows unclear echo free space and flow signal in the fetal echocardiogram. Because of increasing pulmonary blood flow as gestation progresses, color Doppler may make underestimation of the severity of PVO.

DIFFERENTIAL DIAGNOSIS OF ACUTE DYSPNEA: THE USEFULNESS OF TISSUE DOPPLER ECHOCARDIOGRAPHY PERFORMED BY THE EMERGENCY PHYSICIAN IN THE EMERGENCY DEPARTMENT

E. G. Jung², D. U. Kim¹, J. H. Lee², Y. R. Ha¹

¹Dept. of Emergency Medicine, Bundang Jesaeng Hospital,

²Dept. of Emergency Medicine, Seoul National University

Background: In managing acutely dyspneic patients, a rapid differentiation of the underlying disease is important but not easy. Although B-type natriuretic peptide (BNP) is generally accepted as a useful marker, inconclusive results are common.

Objective: We evaluated whether emergency physicians (EP) performed tissue Doppler echocardiography (TDE), which is known as a relatively easy method, is accurate in discriminating between heart and lung diseases in emergency department (ED) dyspneic patients, in comparison to BNP.

Patients and methods: We enrolled ED patients with acute dyspnea and unclear pathology. Initial BNP level and TDE performed by EP were checked prospectively. The ratios of peak early diastolic transmitral blood flow velocity (E) versus the peak early diastolic tissue velocity over mitral annulus (Ea) on TDE were recorded. The sensitivity and specificity of tissue Doppler parameters and BNP levels for diagnosing acute heart failure were calculated and we compared the ability of the two tools in the differential diagnosis.

Results: 49 patients (39 heart failure, 10 respiratory disease) were enrolled. The area under the ROC curves for BNP and E/Ea were 0.946 and 0.888 ($p < 0.001$) respectively. Cut-off values were 350 pg/ml for BNP (sensitivity and specificity of 82.1 and 100%) and 9.0 for E/Ea (89.2 and 100%). However, in the group with low BNP (< 350), BNP was a poor discriminator of the underlying disease, whereas E/Ea was still effective (AUC: 0.943, $p = 0.021$).

Conclusion: TDE by EP is a useful tool for diagnosing acute heart failure in ED and could easily and rapidly discriminate the underlying disease of acutely dyspneic patients, especially in cases of inconclusive BNP levels.

References

- Mueller C, Laule-Kilian K, Frana B, Rodriguez D, Scholer A, Schindler C, et al. Use of B-type natriuretic peptide in the management of acute dyspnea in patients with pulmonary disease. *Am Heart J*. 2006;151:471–7.
- de Lemos JA, McGuire DK, Drazner MH. B-type natriuretic peptide in cardiovascular disease. *Lancet*. 2003;362:316–22.
- Isaaq K, Thompson A, Ethevenot G, Cloez JL, Brembilla B, Pernot C. Doppler echocardiographic measurement of low velocity motion of the left ventricular posterior wall. *Am J Cardiol*. 1989;64:66–75.
- Sohn DW, Chai IH, Lee DJ, Kim HC, Kim HS, Oh BH, et al. Assessment of mitral annulus velocity by Doppler tissue imaging in the evaluation of left ventricular diastolic function. *J Am Coll Cardiol*. 1997;30:474–80.
- Kim YJ, Sohn DW, Oh BH, Lee MM, Park YB, Choi YS, et al. Clinical utility of mitral annulus velocity to estimate left ventricular filling pressure. *J Korean Soc Echocardiogr*. 1998;6:145–51.

ROLE OF ULTRASOUND IN CONFIRMATION OF ENDOTRACHEAL TUBE POSITION IN THE EMERGENCY DEPARTMENT

W. A. Malik, S. Wazir, V. P. Chandrasekaran, S. A. Bhat

Dept. of Accident and Emergency Medicine, Columbia Asia hospital, Gurgaon

Background: Securing airway by an endotracheal tube is of utmost importance in emergency setting. Nevertheless, confirmation of tube

also bears great weightage in emergency department (ED). Time factor is very crucial one in such a setting. Bedside lung ultrasound (US) helps in not only saving time but also helps in confirmation of it. Efficacy of the US may be enhanced if performed and interpreted by the physician in charge.

Aim: Role of US in confirmation of endotracheal (ET) tube position in the ED.

Material and methodology: It is a prospective comparative study done in our hospital from February 2009 to July 2010. All the patients who presented to our ED and who required elective ET intubation were enrolled in this study. Thoracic US was performed in all phases of intubation i.e. pre-oxygenation, pre-medication, intubation and post intubation. To obtain a standardized image, the transducer was placed between the third and fourth intercostal space of the left, and then the right hemi-thorax. All patients were submitted to bedside portable hand held US by using CHIZON for confirmation of ET tube position. Presence or absence of the lung sliding and comet-tail artifacts was determined and considered as focal point of the study. Finally, all patients were submitted to chest X-ray and clinical examination to assess the position of ET tube and to compare the findings obtained by thoracic US.

Results: 65 patients were included in the study. Out of them, 5 patients were excluded due to incomplete data collection. Out of 60 patients, 43 patients had regular lung sliding, while 17 showed absence of it. On clinical examination, 55 patients had B/L equal air entry and 5 patients had B/L unequal air entry. Comparison with chest X-ray confirmed that 41 patients had correct position of ET tube, whereas 19 patients had right main stem intubation. Thus, comparing the data between lung US and chest X-ray confirmed that there is a role for lung US in confirmation of ET tube position.

Conclusion: From the abovementioned variables and data it is evident that hand held US is helpful in confirming the correct position of ET tube in emergency. It is not only an easy method, but also repeatable, quick and trust worthy.

INCIDENCE OF POSTERIOR WALL PENETRATION DURING INTERNAL JUGULAR CANNULATION: A COMPARISON OF TWO TECHNIQUES USING REAL TIME ULTRASOUND

S. Srinivasan, D. Govil, S. Bhatnagar, S. Gupta, S. Patel, J. KN, Y. Mehta

Institute of Anaesthesiology and Critical Care, Medanta the Medicity, Gurgaon, Haryana, India

Background: The true incidence of penetration of the posterior wall of the internal jugular vein (IJV) during cannulation is unknown. This usually benign event may have severe complications if there is associated penetration and inadvertent cannulation of an underlying carotid artery [1]. Multiple studies have demonstrated an improved success rate and a decreased complication rate for ultrasound-guided vascular access as compared to the traditional landmark technique [2].

Objective: To compare the frequency of posterior wall puncture during IJV cannulation by using ultrasound guidance v/s traditional landmarks guided technique.

Patients and methods: 30 adult patients admitted in a Gastro-Liver ICU were randomly divided in two groups (n = 15). Group A: IJV cannulation using anatomical landmark guided technique; Group B:

IJV cannulation using real time ultrasound guidance. In both groups a second investigator handled the ultrasound probe.

Result: 8/15 (53%) patients in group A had posterior wall puncture compared to 3/15 (20%) in group B. Incidence of arterial puncture was 2/15 (13%) in group A, 1/15 (7%) in group B.

Conclusion: Real time Ultrasound guided internal jugular line placement may help reduce the incidence of posterior venous wall penetrations.

References

1. Blaivas M, Adhikari S. An unseen danger: frequency of posterior vessel wall penetration by needles during attempts to place internal jugular vein central catheters using ultrasound guidance. *Crit Care Med.* 2009;37:2345–2349.
2. Karakitsos D, et al. Real-time ultrasound guided catheterisation of the internal jugular vein: a prospective comparison with the landmark technique in critical care patients. *Crit Care.* 2006;10:R162

VOLUME STATUS EVALUATION BY INFERIOR VENA CAVA ULTRASOUND PERFORMED BY NEPHROLOGIST

J. M. Pazeli Jr^{1,2}, T. C. Grossi², N. M. Fernandes¹, R. B. de Paula¹, H. Sanders-Pinheiro¹

¹Division of Nephrology, Federal University of Juiz de Fora, Minas Gerais, Brazil. Núcleo Interdisciplinar de Estudos e Pesquisas em Nefrologia (NIEPEN), Juiz de Fora, Minas Gerais, Brazil

²WINFOCUS/Brazil

Background: The expiratory diameter of inferior vena cava (IVC) and its collapse during inspiration assessed by ultrasound (US) correlate to central venous pressure and to dry weight of dialysis patients. The availability of cardiologists and the costs of the cardiac US has hindered its use. A trend of using US by noncardiologists increased the interest in evaluating the IVC as a parameter of volume status in dialysis patients.

Objective: To evaluate whether the volume status through expiratory IVC diameter and its inspiratory collapse (IC) performed by a nephrologist, without formal training, using conventional US equipment is similar to conventional examination carried out by echocardiographist using an echocardiograph with all resources.

Patients and methods: In a cross-sectional study, 14 patients were evaluated during their hemodialysis session, sequentially by the two researchers, blindly, with a minimum time between exams; each investigator evaluated the same patient on two occasions using both equipments. Subjects were classified by the diameter (VCD) and IC of the IVC in hypovolemic, normovolemic, or hypervolemic (Cherix 1989) and measures made by the echocardiographer and nephrologist were compared by Chi-square, intraclass correlation coefficient, t test and Pearson's correlation coefficient.

Results: The volemic status assessed by VCD and by IC were similar, both to between observers and equipment. The intraclass correlation coefficient was high, for conventional US (0.94 and 0.97) and for echocardiograph (0.89 and 0.95). The correlation coefficient to equipments was also high, 0.93 and 0.99 to the nephrologist and 0.97 and 0.99, to the cardiologist. The value of the VCD and IC measures performed by the two analyzers showed great similarity, by t and Pearson correlation tests.

Conclusion: The IVC studies by US carried out by a nephrologist performed equally as conventional method. These findings corroborate that evaluation of the IVC by nonimagingologists can be used to estimate dry weight in dialysis patients.

References

1. Brennan JM. Handcarried ultrasound measurement of the inferior vena cava for assessment of intravascular volume status in the outpatient hemodialysis clinic. *Clin J Am Soc Nephrol.* 2006;1(4):749–753. doi:10.2215/CJN.00310106.
2. Moore CL, Copel JA. Point-of-care ultrasonography. *New Engl J Med.* 2011;364(8):749–757. doi:10.1056/NEJMr0909487.

POINT OF CARE OPTIC NERVE ULTRASOUND: TRUE IMAGES AND FALSE MEASUREMENTS

P. Previtali¹, G. Ganci², A. Lauro³, L. Neri¹, G. Via⁴, E. Storti¹

¹Department of Anesthesia and Intensive Care, Niguarda Ca' Granda Hospital, Milan, Italy

²Department of Neuroradiology, Niguarda Ca' Granda Hospital, Milan, Italy

³Department of Radiology, Padua Hospital, Italy

⁴Department of Anesthesia and Intensive Care, IRCCS Policlinico San Matteo, Pavia, Italy

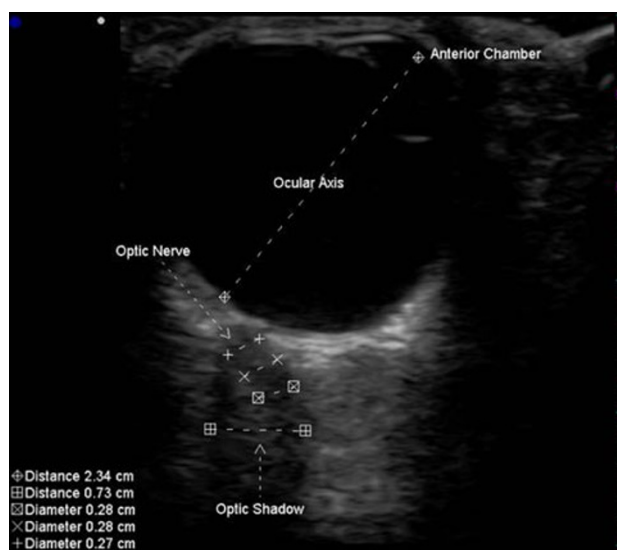
Background: The optic nerve (ON) is enveloped by a sheath (ONS) of meninges and is surrounded by cerebrospinal fluid (CSF) in connection with intracranial subarachnoid space. CSF pressure influences optic nerve sheath diameter (ONSD), and several studies have investigated the relationship between its ultrasound (US)-measured diameter and intracranial pressure (ICP). Previous works, validating negative predictive cutoffs for intracranial hypertension (ICH), seem however to have measured an artifact (the acoustic shadow of the papilla, which runs centrally and straight) rather than the real ON (serpiginous and with a medial course). Cerebral MRI imaging and retinal artery color Doppler studies seem to support this technical inconsistency.

Objectives: Redefinition of ultrasound method for ON identification and measurement, with a US-MRI correlation study.

Patients and methods: Prospective observational study on 20 outpatients without ICH, submitted to cerebral MRI. We performed an ocular US study with a 16 MHz probe just before the MRI, and identified in all patients the ON, with its serpiginous and medial course. We measured the central hypoechoic portion only, which represents the ON. We compared US-measured (OND-US) with MRI-measured (OND-MRI) ON diameter, taking the latter as gold standard.

Results: 40 OND MRI and US measurements have been obtained, from 20 patients. OND-US was 2.7 ± 0.29 mm (range 1.90–3.30 mm) whilst by cerebral MRI it was 2.72 ± 0.34 mm (range 1.83–3.33 mm). The Bland–Altman Plot demonstrates, for these measurements, a good correlation.

Conclusion: We identified with US true anatomical location, course and size of the ON in patients without ICH, confirming discrepancy with what previous studies described as US appearance of the ON. Even if requiring confirmation by comparison of the different ONSD measurement techniques (ON sheath space is virtual in healthy subjects) our data cast serious shadows on data on ONSD acquired with the methodology adopted by previous studies. To our knowledge, this is the first study comparing MRI and US in ON assessment.



Left ON ultrasound image. The medial and oblique course of the optic nerve in contrast to the acoustic shadow.

A PROSPECTIVE EVALUATION OF “FOCUSED ASSESSMENT WITH SONOGRAPHY FOR TRAUMA” DONE BY EMERGENCY NURSES AND ITS COMPARATIVE ANALYSIS WITH RADIOLOGISTS PERFORMANCE

S. Bhoi, S. Chauhan, Shakuntla, Geeta, V. Shoukkathali, Vishnu, T. P. Sinha, R. K. Ramchandani
Presenting Author: S. Chauhan
Email: sonia.autls@gmail.com

Department of Emergency Medicine, Jai Prakash Narayan Apex Trauma Centre, All India Institute of Medical Sciences, New Delhi 29

Objective: To determine the accuracy of emergency nurses in detecting free fluid in abdomen when compared to radiologist during primary survey of trauma victims by focused assessment with Sonography for trauma (FAST) scan in the Emergency Department (ED).

Methods: This was a prospective study performed during the primary survey of resuscitation of non consecutive patients in the resuscitation scenario. The study subjects included emergency Nurses (EN) who underwent training at 3-days workshop on emergency sonography and performed 10 supervised positive and negative scans for free fluid. The FAST scans were first performed by the EN's and then by radiology resident (RR). Both were blinded to each other's sonographic findings. CT scan and laparotomy findings were used as gold standard whenever were feasible. Results were compared between both groups.

Results: 94 scans performed both by EN and RR were analyzed. Mean age of the patients was 29 (from 2 to 85) years. Out of 23 true positive patients 18 underwent CT scan and exploratory laparotomy was done in 14 patients. Sensitivity of FAST done by EN and RR was 90%. Specificity of FAST done by EN was 94.6% versus RR. Positive predictive value and negative predictive values were 81.8 and 97.2% respectively. Limitation: Inter-observer variability was not studied.

Conclusion: FAST scan performed by EN who are trained in short course of ultrasonography can be reliable and accurate when compared to qualified radiologist.

Keywords: Focused assessment with sonography in trauma, Emergency Nurses, Radiologist.

A PROSPECTIVE EVALUATION OF “FOCUSED ASSESSMENT WITH SONOGRAPHY FOR TRAUMA” DONE BY EMERGENCY PHYSICIANS AND ITS COMPARATIVE ANALYSIS WITH RADIOLOGISTS PERFORMANCE

R. K. Ramchandani, T. P. Sinha, S. Bhoi

Presenting Author: R. K. Ramchandani

Email: drramchandani@gmail.com

Department of Emergency Medicine, Jai Prakash Narayan Apex Trauma Centre, All India Institute of Medical Sciences, New Delhi 29

Objective: To determine the accuracy of emergency physicians in detecting free fluid in abdomen when compared to radiologist during primary survey of trauma victims by focused assessment with sonography for trauma (FAST) scan in the emergency department (ED).

Methods: This was a prospective study performed during primary survey of resuscitation of non consecutive patients in the resuscitation scenario. The study subjects included emergency physicians (EP) [1 consultant emergency medicine (EM), 2 EM residents, 1 orthopaedic resident and 1 surgery resident] who underwent training at 3-day workshop on emergency sonography and performed 10 supervised positive and negative scans for free fluid. The FAST scans were first performed by the EP's and then by radiology residents (RR). Both were blinded to each other's sonography findings. CT scan and laparotomy findings were used as gold standard whichever was feasible. Results were compared between both groups. Intra-observer variability among EP's and level of agreement between EP's and RR's were assessed.

Results: 150 scans performed each by EP and RR were analyzed. Mean age of the patients was 28 (from 1 to 70) years. Out of 24 true positive patients 18 underwent CT scan and exploratory laparotomy was performed on 6 patients. Intra-observer performance variation ranged from 87 to 97%. Sensitivity of FAST done by EP and RR was 100%. Specificity of FAST done by EP was 95.4 versus 98.4% by RR. Level of agreement was 100%.

Conclusion: This study proves that FAST scan performed by EP who are trained in short course of ultrasonography can be reliable and accurate when comparable to qualified radiologist.

Keywords: Focused assessment with sonography in trauma, Emergency physician, radiologist.

DIAGNOSTIC ACCURACY OF BEDSIDE ULTRASOUND DONE BY NURSES FOR IDENTIFYING FRACTURES IN PATIENTS WITH ORTHOPAEDIC TRAUMA PRESENTING TO EMERGENCY DEPARTMENT OF A LEVEL 1 TRAUMA CENTRE

Shakuntla, S. Bhoi, T. P. Sinha, R. K. Ramchandani, G. Adhikari, V. Shoukkathali, S. Chauhan, K. Arun, Vishnu, S. Galwankar

Presenting Author: S. Sundriyal

E-mail: shakuntla_aiims@yahoo.com

Department of Emergency Medicine JPN Apex Trauma Centre, All India Institute of Medical Sciences, New Delhi, India

Address for Correspondence

S. Bhoi

Department of Emergency Medicine, JPN Apex Trauma Centre, All India Institute of Medical Sciences, New Delhi, India

Email: sanjeevbhoi@gmail.com

Tel-9868397053

Background: Radiography is the standard observation tool for examining orthopaedic injuries. Bedside Ultrasound (BUS) may be a faster, non-invasive alternative to effectively identify bone fractures in the emergency department (ED) setting. Nowadays BUS is mainly performed by the emergency physicians (EPs). This study compares the diagnostic utilities of BUS performed by ED nurses with radiography for identifying long bone fractures.

Methods: Prospective observation study with convenience sampling was conducted in the ED on patients above 17 years, with post-traumatic upper and lower limb injuries, who required standard radiological examination after informed consent. The BUS examinations were performed by four ED nurses who had a brief training session to detect fractures. Blinded orthopedic specialists reviewed all the radiographs for the presence of fracture. Statistical analysis was done by SPSS.

Results: 30 patients were enrolled in the study. 21 had fracture, out of which 19 were picked up by BUS. The overall sensitivity of the BUS in detecting fracture was 90.4% with a confidence interval (CI) of 0.68–0.98 and specificity of 77.7% with a CI (0.40–0.96). The positive predictive value (PPV) of USG was 90.47% and negative predictive value (NPV) of 77.77%. There were 2 fractures, which were recognized on X-ray and were not detected by ultrasound.

Conclusion: Bedside ultrasonography can be utilized by emergency nurses after brief training to accurately identify long bone fractures. It may gain a more prominent role in pregnant and pediatric population as well as in mass casualty scenarios.

Keywords: Orthopedic trauma, Fracture, Bed side ultrasound, Emergency nurse

ACCURACY OF BEDSIDE ULTRASOUND DONE BY EMERGENCY NURSE TO RULE OUT TRAUMATIC PNEUMOTHORAX IN THE EMERGENCY DEPARTMENT

G. Adhikari, S. Bhoi, T. P. Sinha, R. K. Ramchandani, Shakuntla, V. Shoukkathali, S. Chauhan, K. Arun, Vishnu, S. Galwankar

Presenting Author: G. Adhikari

E-mail: geeta_aiims@yahoo.com

Department of Emergency Medicine, JPN Apex Trauma Centre,
All India Institute of Medical Sciences,
New Delhi, India

Address for Correspondence

S. Bhoi

Department of Emergency Medicine, JPN Apex Trauma Centre,
All India Institute of Medical Sciences, New Delhi, India
Email: sanjeevbhoi@gmail.com
Tel-9868397053

Background: Early detection of pneumothorax is important in the clinical management of trauma patients. The sensitivity of supine anterior/posterior (A/P) chest radiograph is 60%. Diagnosis of tension pneumothorax is mainly a clinical process. Point of care ultrasound can provide answers in critical situations.

Objectives: To study the sensitivity and specificity of bedside ultrasound (BUS) performed by emergency nurse in the emergency department to rule-out pneumothorax when compared to chest X-ray.

Method: Prospective observational study done at a Level 1 trauma from January 2011 to March 2011. All adult trauma patients with stable vital signs were recruited randomly. Four Emergency Department nurses (who had adequate training on the signs of pneumothorax on ten positive and ten negative supervised scans) performed BUS examinations using a linear probe with frequency 7–10 MHz. The main target was looking for lung sliding and the sea-shore sign. Trained and expert Emergency consultants reviewed the recorded findings. A/P chest radiographies were performed after the BUS and then evaluated by an attending emergency physician blinded to the results of the ultrasound examination. The CT results or air release on chest tube placement, whenever feasible, were compared with BUS and chest radiograph findings. Sensitivity, specificity, Negative predictive value, positive predictive value and inter-observer variability were calculated by using SPSS-16.

Results: In 30 patients, total 60 scans were performed. EN ruled out pneumothorax with 100% sensitivity (CI 92–100%) and 100% specificity (CI 39–100%) when compared with consultant emergency department observation and chest radiographs. There was no inter-observer variability.

Conclusion: Emergency Nurses can rule out pneumothorax with high degree of reliability after adequate training.

Keywords: Emergency department nurses, Bedside ultrasound, Pneumothorax

FEASIBILITY AND SAFETY OF ULTRASONOGRAPHY-GUIDED NERVE BLOCKS PERFORMED BY EMERGENCY PHYSICIANS IN THE EMERGENCY DEPARTMENT

S. Bhoi, T. P. Sinha, R. K. Ramchandani

Presenting Author: S. Bhoi

Corresponding Author: S. Bhoi

Email: sanjeevbhoi@gmail.com

Department of Emergency Medicine, Jai Prakash Narayan Apex
Trauma centre, All India Institute of Medical Sciences, New Delhi 29

Background: Patients require procedural sedation and analgesia (PSA) for the treatment of acute traumatic injuries. PSA can have complications. Ultrasound (US) guided peripheral nerve block is a safe alternative.

Aim: Ultrasound guided nerve blocks for management of traumatic limb emergencies in Emergency Department (ED).

Setting and design: Prospective observational study conducted in the ED.

Material and methods: Patients above 5 years requiring analgesia for management of limb emergencies were recruited. Emergency Physicians trained in US guided nerve blocks performed the procedure.

Statistical analysis: Effectiveness of pain control, using visual analogue scale was assessed at baseline and at 15 and 60 min after the procedure. Paired *t* test was used for the comparison.

Results: 154 US guided nerve blocks were brachial ($n = 55$; 35.71%), sciatic (31; 20%), femoral (45; 29.22%), median (8; 5.19%), Fascia Iliaca compartment block (7; 4.54%) and radial (2; 4%) nerves. No patients required rescue PSA. Initial median VAS score was 9.5 [Inter Quartile Range (IQR) 7–10] and at 1 h was 1.26 (IQR 0–4). Median reduction in VAS score was 8.24 [IQR 8–10 (75%); 1–2 (25%); $P = 0.0001$]. Median procedure time was 9.3 min (IQR 3, 12 min) and median time to reduction of pain was 7.19 min (IQR 1, 15 min). No immediate or late complications were noticed at 3 months.

Conclusion: Ultrasound guided nerve blocks can be safely and effectively performed for upper and lower limb emergencies by emergency physicians with adequate training.

Keywords: Feasibility, Safety, Ultrasonography-guided nerve blocks, Emergency physician

FEASIBILITY OF OCULAR SONOGRAPHY PERFORMED BY EMERGENCY PHYSICIANS TO DETECT EYE INJURIES IN TRAUMA VICTIMS IN THE EMERGENCY DEPARTMENT OF A LEVEL-1 TRAUMA CENTER

T. P. Sinha, R. K. Ramchandani, S. Bhoi

Presenting Author: T. P. Sinha

Email: drsinha123@gmail.com

Department of Emergency Medicine, Jai Prakash Narayan Apex
Trauma Centre, All India Institute of Medical Sciences, New Delhi 29

Background: Ocular injuries are common in trauma victims but often misdiagnosed. Early identification of the injury and call for the ophthalmologist are the key-points.

Objective: Feasibility of ocular sonography as an adjunct to physical examination.

Methods: All trauma victims with head and maxillofacial injuries presenting to the emergency department were recruited for ocular scan. Patient with lid laceration and/or penetrating injuries to the eye were excluded. The emergency physician (EP) underwent 3 days of emergency sonography training including ocular scan. The EPs performed 20 supervised ocular scan to identify anterior chamber, lens, vitreous, retina, optic disc and calculation of optic nerve sheath diameter before inclusion to the study. Four residents and one consultant emergency medicine performed the scan. The examination was performed following the Alara principles during the secondary survey of trauma resuscitation, by 7–10 MHz linear probe in transverse plane. The images as well as the video clips were recorded. The ophthalmologist then performed a blinded review. Non-contrast CT head and face were performed as per protocol.

Results: Out of eighty-nine patients, five (5.6%) had ocular injuries. 83 were males. Two patients had vitreous hemorrhage, one had partial globe rupture, one had complete globe rupture and one had retinal detachment. The average bilateral optic nerve sheath diameter in patients with traumatic brain injury was 4.8 mm. The level of agreement among EPs and Ophthalmologists was 100%.

Conclusion: Emergency physicians can identify abnormal ocular scans. Ocular scan should be an adjunct to clinical examination during secondary survey of trauma resuscitation.

Keywords: Ocular sonography, Emergency physician, Feasibility

THE AVERAGE OPTIC NERVE SHEATH DIAMETER AT OCULAR SONOGRAPHY ON NON-HEAD INJURY PATIENTS AND HEALTHY VOLUNTEERS AND ITS CORRELATION WITH AGE GROUP, RACE AND GENDER

R. K. Ramchandani, T. P. Sinha, S. Bhoi
Presenting Author: R. K. Ramchandani
Email: drramchandani@gmail.com

Department of Emergency Medicine, Jai Prakash Narayan Apex Trauma Centre, All India Institute of Medical Sciences, New Delhi 29

Background: Optic nerve sheath diameter (ONSD) is emerging as a new parameter for assessment of increased intracranial pressure (ICP). Bilateral normal average ONSD in Caucasians is 5 mm in adult and 4–4.5 mm in pediatric age group. Bilateral average ONSD correlates with ICP of 20 mmHg ($r = 0.9$). The average ONSD may vary among race, age and gender.

Objective: To study the average optic nerve sheath diameter diagnosed at sonography and its correlation with age groups, race and gender.

Methods: Adult healthy volunteer and non-head injury patients of either sex were recruited after consent. Pediatric age group were excluded. The ONSD was calculated from 3 mm behind the globe. Four residents and one consultant emergency medicine performed the scan. The scan was performed as per Alara principles by using 7–10 MHz linear probe and transverse planes. The images were recorded and the ophthalmologist did blinded reviews.

Results: Data of 49 non-head injury and healthy volunteers were analyzed. 91% were males. The right ONSD was 4.17 mm and left was 4.08 mm and bilateral average was 4.1 mm among males. The left ONSD was 4.1 ± 0.4 mm, right ONSD was 4.1 ± 0.5 mm and bilateral average was 4.07 mm among females. The average age group was 28 years (from 13 to 83) years. In adult group (13–40) years right ONSD was 4.1 mm and left was 4.06 mm with bilateral average of 4.09 ± 0.3 mm. Right ONSD was 4.2 mm, left ONSD 4.3 mm with bilateral average of 4.2 ± 0.4 mm was observed in middle age group (41–65) years. In geriatric age group (≥ 66) years, right ONSD was 4.6 mm, left ONSD was 4.4 mm with bilateral average of 4.5 ± 0.3 mm. The overall bilateral average ONSD was 4.1 ± 0.3 mm.

Limitation: Small sample size.

Conclusion: The overall bilateral average ONSD is 4.1 ± 0.3 mm among adult Indian population. There is no difference in ONSD pertaining to different age groups and gender.

Keywords: Ocular Sonography, Optic nerve sheath diameter, Emergency physician

EFFICACY OF OPTIC NERVE SHEATH DIAMETER MEASUREMENT BY OCULAR SONOGRAPHY TO DETECT RAISED INTRACRANIAL PRESSURE IN HEAD INJURY PATIENTS IN THE EMERGENCY DEPARTMENT

S. Bhoi, T. P. Sinha, R. K. Ramchandani
Presenting Author: S. Bhoi
Corresponding author: S. Bhoi
Email: sanjeevbhoi@gmail.com

Department of Emergency Medicine, Jai Prakash Narayan Apex Trauma Centre, All India Institute of Medical Sciences, New Delhi 29

Background: Optic nerve sheath diameter (ONSD) may be an effective tool to detect increased intracranial pressure (ICP) especially in unstable patients in emergency care.

Objective: To study the efficacy of ONSD measurement by using ocular sonography to detect raised ICP traumatic brain injury (TBI).

Methods: Adults patients with head injury presenting to the emergency department were recruited. Patients with lid laceration and penetrating eye injuries were excluded. The ONSD was calculated from 3 mm behind the globe. Four residents and one consultant emergency medicine performed the scan. The study was performed as per Alara principles after consent by using 7–10 MHz linear probe in transverse plane. The images were recorded and the ophthalmologist performed blind reviews. Cases with midline shift and gyri effacement findings on CT were considered to have increased ICP. Comparison of bilateral average ONSD was done between raised ICP and normal ICP group. Control group was average ONSD from normal population.

Results: Out of 93 patients 84 patients' data were analysed. Out of 84 patients, 72 (85.5%) had increased ICP and 14 (15.5%) had no evidence of increased ICP on CT. The average ONSD were 5.1 ± 2.6 versus 4.5 ± 0.7 mm in normal ICP patients and 4.1 ± 0.3 mm in control patients. 72% patients with increased ICP had severe TBI with bilateral average ONSD were 5.04 ± 0.9 versus 4.1 ± 0.3 mm in control patients. There was a significant relationship between the largest ONSD and ICP at admission ($r = 0.68$). The largest ONSD was a suitable predictor of high ICP (area under ROC curve 0.96). When ONSD was less than 4.5 mm, the sensitivity and negative predictive values for high ICP were 100%.

Limitation: Operator dependence. ICP pressure monitoring was not done.

Conclusion: Ocular ultrasound scans may be useful for detecting high ICP after traumatic brain injury.

Keywords: Ocular Sonography, Emergency physician, Optic nerve sheath diameter

BASELINE OPTIC NERVE SHEATH DIAMETER AS A PREDICTOR OF OUTCOME IN TERMS OF SURVIVAL IN PATIENTS WITH SEVERE TRAUMATIC BRAIN INJURY

T. P. Sinha, R. K. Ramchandani, S. Bhoi
Presenting Author: T. P. Sinha
Email: drsinha123@gmail.com

Department of Emergency Medicine, Jai Prakash Narayan Apex Trauma Centre, All India Institute of Medical Sciences, New Delhi 29

Background: Glasgow coma scale (GCS) at arrival is a tool to classify, risk stratifies head injury patients. GCS has its pitfalls. Optic nerve sheath diameter measurements are a method to detect increased intracranial pressure (ICP).

Objective: To study baseline optic nerve sheath diameter as predictor of outcome in terms of survival and death in patients with severe traumatic brain injury (TBI).

Methods: Adults patients with head injury presenting to the emergency department were recruited. Patients with lid laceration and penetrating eye injuries were excluded. The ONSD was calculated from 3 mm behind the globe. Four residents and one consultant

emergency medicine performed the ultrasound scan. The scan was performed as per Alara principles after having obtained the consent. Linear probe 7–10 MHz and transverse planes were used to examine the patients. The images were recorded and then the ophthalmologist performed blind reviews. Midline shift and gyri effacement on CT were considered signs of raised ICP. The outcome of patients was noted in terms of survival. Patients were excluded in case of missing data and pediatric subjects were not enrolled. The variable such as age, sex, GCS, head injury class, CT, increased ICP and average ONSD were compared as survivor or non-survivor group.

Results: Out of 89 patients, 45 patients data could be analyzed, as 39 patients were lost to follow up and 5 were pediatric patients. Among 45 patients, 30 (66.6%) survived and 15 (33.3%) died. Minor TBI (30%), moderate TBI (20%) and severe TBI were 50% while the average GCS was 9 (3–15) in the survivors group. CT was positive for increased ICP in 83.3% with bilateral average ONSD of 4.9 ± 0.6 mm (3.2–8) mm among the survivors. Moderate TBI (13.3%) and severe TBI were 86.6% with an average GCS of 5 (3–10) among non-survivors. CT studies were positive for raised ICP in 100% cases with average ONSD 4.9 ± 2.8 mm (3.6–6.5) mm. The average ONSD in severe TBI among survivors 5.03 ± 0.6 and non-survivors group were 4.9 ± 2.8 mm.

Conclusion: Baseline bilateral average ONSD is not a predictor of outcome in terms of survival or death in head injury.

Keywords: Ocular Sonography, Emergency physician, Optic nerve sheath diameter

LEFT VENTRICLE CARDIAC HEMANGIOMA PRESENTING WITH MINISTROKE

¹S. Noura, ²Y. Harrath, ³A. Chokki, ⁴R. Zribi

Siliana Regional Hospital, Siliana 6100, Tunisia

Background: Cardiac hemangioma is a rare condition and represents 5–10% of all benign primary cardiac tumors. Left ventricular involvement is uncommon.

Objective: To show how cardio vascular imaging (echocardiography, CT, MRI) played an important role in the diagnosis of cardiac hemangioma.

Case report: A 35 year-old healthy man referred to our emergency department with transient ischemic attack (TIA). He presented monocular blindness and aphasia. The medical history, physical exam, workup, surgical approach and outcome are discussed. Physical examination: systolic murmur heart. Electrocardiogram, chest X-ray, echodoppler exploration of the neck vessels and cerebral CT scan showed no abnormalities. By echocardiography (transthoracic and transesophageal) we detected a mass of 3 cm diameter localized in the left ventricle. MRI was performed to determine the tumor's tissue type and its relationship to cardiac structures. The tumor was removed by open-heart operation and cardio-pulmonary by pass. The postoperative outcome was favorable. Histopathological examination revealed that the tumor was a capillary cardiac hemangioma.

Conclusion: Cardiac hemangioma of the left ventricle is an extremely rare condition that may present with neurological manifestations. Diagnosis is facilitated by echocardiography followed by contrast enhanced CT or MRI studies.

References

- Nematl MH. Cardiac hemangioma presenting with neurological manifestations. *Gen Thorac Cardiovasc Surg.* 2009;57:155–158.
- Eteychion C, Autoniates L. Cardiac hemangioma in the left ventricle and brief review of the literature. *J Cardiovasc Med.* 2009;10:565–7.
- Kocak H, Ozyazicioglu A, et al. Cardiac hemangioma complicated with cerebral and coronary embolization. *Heart Vessels.* 2005;20:296–7.
- Marrone G, Sciacca S. A rare case of left ventricular intra mural hemangioma diagnosed using 1.5 T cardiac MRI. *Cardiovasc Intervent Radiol.* 2010;33:164–8.

ROLE OF ROUTINE BEDSIDE ULTRASOUND FOR PATIENTS WITH FLANK PAIN IN THE EMERGENCY DEPARTMENT

W.-J. Lee, Y.-Z. Cheng, H.-J. Lin

Department of Emergency Medicine, Chi-Mei Medical Center, Yong-Kang City, Tainan, Taiwan 71084

Background: Acute onset of flank pain is the classical presentation of nephrolithiasis. Nontraumatic vascular emergencies, such as rupturing or enlarging abdominal aortic aneurysm and dissecting aortic aneurysm that involves descending aorta, may also present with similar symptom of flank pain. A protocol of routine bedside ultrasound by emergency physician is a useful screening tool in such setting to prevent catastrophe.

Methods: Patients presenting to the emergency department with acute onset of flank pain receive routine bedside ultrasound by emergency physician in accordance with our emergency department protocol for suspected diagnosis of renal colic (Fig. 1). Further disposition will be arranged depending on the bedside ultrasound findings and the emergency department protocol.

Case report: A 48-year-old man with history of hypertension and urolithiasis presented to the emergency department early in the morning complaining of sudden onset left flank pain accompanied by cold sweating. There was no tearing pain. Routine bedside ultrasound was performed in accordance to the emergency department protocol for renal colic. Moderate hydronephrosis with hydroureter was noted along with abdominal aorta with intimal flap (Figs. 2, 3). A CT scan of the abdomen was then performed, which confirmed the diagnosis of dissecting aortic aneurysm type B and left mid-third ureteral stone with obstructive uropathy (Fig. 4).

Discussion: Ultrasound is a useful screening tool in the hands of the emergency physicians, particularly when facing with patients who are not candidates for contrasted CT study. It is portable, easy accessible, noninvasive, and free from radiation exposure. Mortality is extremely high for ruptured abdominal aortic aneurysm and dissecting abdominal aorta. Emergency physician must be able to recognize this life-threatening condition by using bedside ultrasound. Emergency physician who is trained in sonography is the best candidate to utilize bedside ultrasound for immediate analysis and treatment of many life-threatening conditions. We provide a bedside ultrasound protocol for all our emergency residents to follow and advocate routine bedside ultrasound screening for all the patients with flank pain.

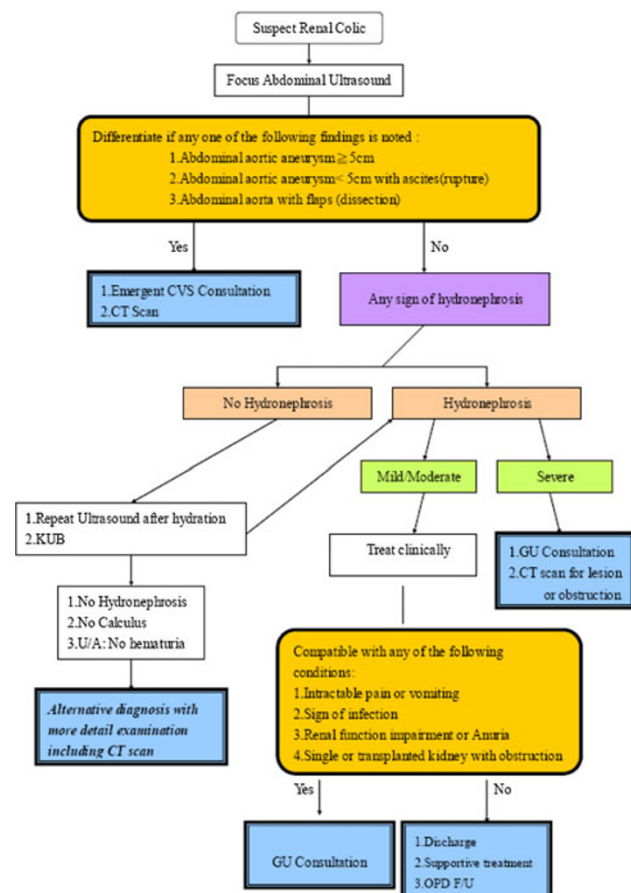


Fig. 1 Protocol for patients with sudden onset of flank pain. Routine bedside ultrasound is performed by the emergency physician

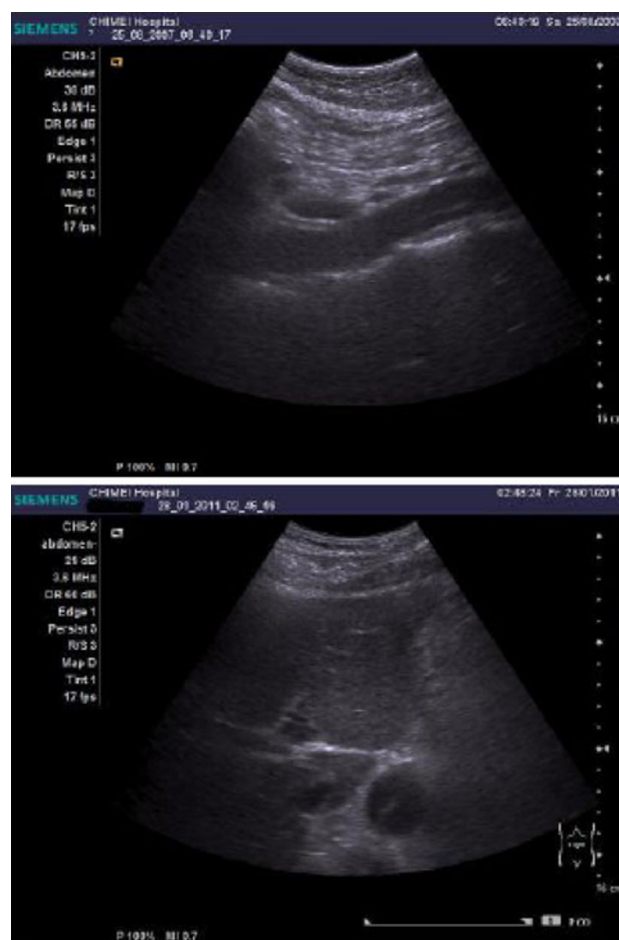


Fig. 3 Bedside ultrasound showed intimal flap of the abdominal Aorta

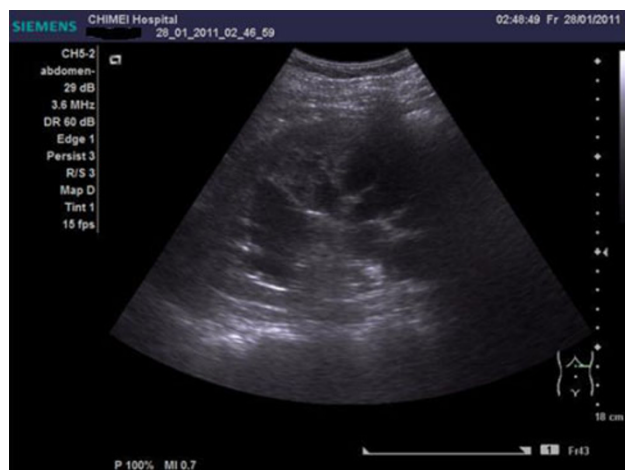

Fig. 2 Bedside ultrasound performed by emergency physician showed moderate Hydronephrosis of left side kidney

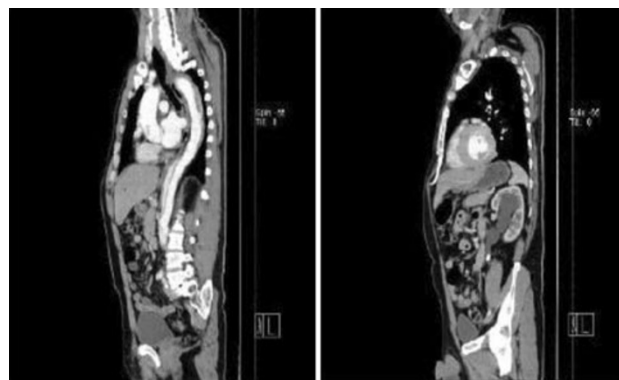


Fig. 4 CT scan of the abdomen showed dissecting abdominal aorta type B And left mid-third ureteral stone with obstructive uropathy

Abstracts for 5th Winfocus Italy Congress

DIFFUSE AND PERSISTENT SPONTANEOUS ECHO CONTRAST IN THE VENOUS SYSTEM ASSOCIATED WITH MASSIVE PULMONARY EMBOLISM AND B-CELL CHRONIC LYMPHOCYTIC LEUKAEMIA PRODUCING IGA TYPE CRYOAGGLUTININS

P. Pasquero, G. Greco, M. M. Zanone, V. Paganin, E. Sitia, M. Porta

Department of Medicine, S. Giovanni Battista Hospital, Turin, Italy

Background: Spontaneous echo-contrast (SEC) is a phenomenon in which a smoke-like echo appearance with a swirling pattern of blood flow is generated by the interaction between red cells and plasma proteins in conditions of blood stasis or low-velocity blood conditions [1].

SEC is observed most often within the right heart chambers in patients with thromboembolism, atrial fibrillation, severe mitral stenosis, reduced cardiac index, dilated cardiomyopathy, cerebrovascular accidents and increased plasma viscosity.

Case report: A bedside point of care ultrasound (POC-US) examination was able to define and to follow SEC in the right cardiac chambers, inferior vena cava and femoral veins of an 86 year old man, on oral anticoagulation because of chronic atrial fibrillation, with a final diagnosis of pulmonary embolism and B-cell chronic lymphocytic leukaemia producing IgA type cryoagglutinins.

Persistence of smoke like echo phenomena in the central and peripheral venous system was observed in the following days despite heparin and steroid administration. Only after the introduction of Chlorambucil a clinical improvement was obtained, accompanied by disappearance of SEC at POC-US monitoring (complete absence of dynamic echo artefacts after 10 days of therapy).

Conclusion: This case report suggests that both marked reduction of blood flow velocity and increased plasma viscosity may cause SEC diffusion and persistence in the venous system. POC-US monitoring proved a useful tool in the clinical and therapeutic management of this patient.

References

- Merino A, et al. Echocardiographic 'smoke' is produced by an interaction of erythrocytes and plasma proteins modulated by shear forces. *J Am Coll Cardiol.* 1992;20:1661–68.

ABDOMINAL PAIN IN A YOUNG FEMALE, THE ROLE OF ULTRASOUND EXAMINATION

G. Ruggiano, R. Camajori Tedeschini, P. Sonni, E. Catini

U.O. Medicina d'Urgenza, Ospedale S. Maria Annunziata, ASL 10 Firenze

Case report: A 44 years old woman presented to our emergency department (ED) for epigastric pain and nausea lasting 3 days. The history of the patient was silent and she did not take any medication, except for oral contraception. The physical examination was normal: she just presented abdominal tenderness. Chest X-ray and

electrocardiogram were normal. The laboratory tests showed only a slight increase of hepatic enzymes and C-reactive protein. An ultrasound (US) E-FAST examination was performed and the result was normal. After 6 h the patient still complained of pain, thus laboratory tests and an abdominal bedside US examination were repeated. US showed splenomegaly and a hypoechoic image in the pancreatic area that extended 3–4 cm longitudinally and that was highly suggestive of superior mesenteric vein thrombosis. A contrast enhanced computed tomography (CT) of the abdomen was then performed, with the specific query for confirming mesenteric vein thrombosis evaluation. The CT study confirmed the US diagnosis and anticoagulant therapy with unfractionated heparin was started. The screening tests for congenital and acquired coagulopathies were all normal and the only identified risk factor was oral contraception.

Discussion: There are a number of reports in the literature that describe the association of venous thrombosis with oral contraceptives. Venous thrombosis is a rare form of mesenteric ischemia that may be lethal if not promptly diagnosed and treated. The clinical features are usually very subtle and often the diagnosis is not easy. When the diagnosis is delayed, very often damage to the small intestine is already present and demolitive surgical intervention is needed.

Ultrasound examination is an extremely useful tool in the hands of the emergency physician in the evaluation of abdominal pain: it can be performed at bedside, can be repeated, is well tolerated and harmless. It is useful in the rapid conclusive diagnosis of life threatening conditions, but can also suggest diagnosis of rare conditions. CT scan remains the gold standard for the diagnosis of vascular disease of the intestine, but sensitivity of this method depends on the accuracy and specificity of the diagnostic question facing the radiologist. Thus, it is very important for the ED physician to gain a good ultrasound competence.

AN ACUTE STROKE NOT TO THOMBOLYSE

R. Camajori Tedeschini, G. Ruggiano, L. Del Bianco

Emergency Department, Ospedale S. Maria Annunziata, Florence

Case report: A 72 years old female was admitted to our emergency department (ED) for acute onset (2 h) of speech disorder and right hemiplegia. She had arterial hypertension, but no other disease.

The physical examination showed global aphasia and right hemiplegia, without other abnormal signs. The Safe Implementation of Thrombolysis in Stroke Monitoring Study (SITS-MOST protocol) was then applied and a head computerized tomography (CT) scan was requested. There were no contraindications to thrombolysis. An ultrasound examination of the epiaortic vessels was performed, extending the AHA/ASA indications for the transient ischemic attack (Stroke 2009;40:2276). At the Doppler ultrasound study, an intimal flap in both common carotid arteries was visualized.

We then performed echocardiography, which showed an aneurismatic dilatation of the ascending aorta with an intimal flap. The thrombolysis protocol was then stopped and a contrast enhanced CT study of thoracic-abdominal aorta was performed. The CT scan confirmed the diagnosis and the patient was admitted to the cardio surgery ward for urgent surgical intervention.

Discussion: In our ED we had four patients with acute ischemic stroke who were candidates to receive thrombolytic treatment, for which the ultrasound examination showed an aortic dissection extending to the epiaortic vessels as the cause of the stroke.

We believe that a bedside ultrasound examination of epiaortic vessel should be performed in every patient before starting thrombolytic treatment, even though attention should be paid to the timing to avoid delaying the proper treatment.

ULTRASOUND EXAMINATION IN CHEST PAIN

C. Poggioni, V. Ponticelli, N. Di Cesare, G. Ruggiano

Emergency Department, Ospedale S. Maria Annunziata, Florence

Case report: A 67 years old male was admitted to our emergency department (ED) complaining of typical chest pain and dyspnea on exertion during the previous week, and one episode of chest pain at rest 10 h before the visit, which lasted for 30 min. He had a past history of arterial hypertension and cigarette smoking. The hearth rate was 107 beats/min and blood pressure was 145/85 mmHg.

The physical examination was normal, and the electrocardiogram showed a T wave inversion on lateral leads. The cardiac enzymes were normal and chest X-ray did not show any significant anomaly. Thus the patient remained in ED for clinical and laboratory periodic assessment possibly followed by a stress test, for ruling-out acute coronary disease.

Following our chest pain protocol, we performed also a bedside E-FAST, that did not show any sonographic sign suggestive of pneumothorax, lung consolidation or pleural effusion, but showed an important circumferential organized pericardial effusion with initial right chambers compression, without any evidence of altered left ventricular contraction. Fluids were administered and ultrasound assisted pericardiocentesis was performed by inserting a pericardial tube. The patient was transferred to the cardiology intensive care unit, where 1.5 liters of pericardial effusion were drained during 24 h. A contrast enhanced chest CT study was performed, which showed a left basal pulmonary lesion highly suspicious for lung cancer.

Discussion: We believe that an ultrasound evaluation of the chest and a bedside echocardiogram should be routinely performed, thus extending the physical examination, during the first visit of patients with chest pain. Literature data show that clinical evaluation alone may not be sufficient to exclude life-threatening conditions and properly direct diagnostic hypothesis. Bedside ultrasound examination is a very useful tool for ED physicians as it is easy to perform, repeatable, and satisfactory for the patient. We believe that every effort should be made to acquire and maintain a high level of ultrasound competence in our work practice that is always complicated and sometimes misleading.

CAN THE ROUTINE USE OF BEDSIDE CHEST ULTRASONOGRAPHY INFLUENCE THE DECISION MAKING PROCESS IN THE EMERGENCY DEPARTMENT?

M. Zanobetti¹, S. Bigiarini¹, A. Guzzo¹, F. Bulletti¹, S. Squarciotta¹, C. Converti¹, R. Pini¹

¹Department of Critical Care Medicine and Surgery, University of Florence, Florence, Italy and Intensive Observation Unit, Careggi University Hospital, Florence, Italy
Azienda Ospedaliero-Universitaria Careggi Largo Brambilla, 3, 350134 Firenze

Background: Bedside chest ultrasonography (US) is a readily available, relatively inexpensive and biologically non-invasive imaging modality that requires a short training and may provide accurate information with diagnostic and therapeutic relevance.

Objective: Aim of this study is to evaluate if chest US can influence the decision making process in the Emergency Department (ED).

Patients and methods: From April to June 2011, 303 consecutive patients admitted to the ED were enrolled in the study. According to the study design, the emergency physician (EP) completed the patient work-up and planned the pharmacological interventions and the diagnostic tests before performing the bedside chest US examination. After the US scanning, the same EP had to reassess his planned actions and to fill out a questionnaire to verify if the US scan modified the original diagnosis (confirmed or modified), the therapeutic plan (confirmed or modified) and the diagnostic orders (unmodified, less or more tests than originally planned). Then, these 3 questions were combined in a variable named “US impact” indicating if at least one of the previous variables were modified. The questionnaire also required a grading the usefulness of chest US.

Results: In 56% of cases, EP considered US very useful (34%) or absolutely essential (22%), despite its rapid execution (9 ± 3 min). US amended the decision making process in 81% of patients, influencing the therapeutic choices in 39% of cases, the request of further diagnostic tests in 26% and the diagnostic hypothesis in 92% (weakened in 37%, strengthened in 55%). The impact of US was significant regardless of the presenting symptoms; as expected, US influenced the decision making process in 95% of subjects with lung disease compared to 57% of subjects with different diagnosis at ED admission ($p < 0.001$). Chest US was fully concordant with physical findings in 31% of cases, discordant in 15% and in 54% of cases US discloses new abnormalities not shown by physical examination. This had interesting practical consequences because the EP changed his suspected diagnosis in 84% of cases of discordance and in 39% of cases in which he/she detected new findings.

Conclusion: In our experience bedside chest US routinely performed by EPs has proven to have enormous potential in influencing the decision making process in ED. This result, combined with its low cost and availability, makes chest US a useful tool in emergency situations.

LUNG ULTRASOUND AFTER CARDIAC SURGERY

A. Vezzani¹, A. Molardi¹, F. Bozzetti², C. Fragnito¹, F. Nicolini¹, M. Zasa¹, T. Manca¹

¹Dipartimento Cardio Nefro Polmonare,
Terapia Intensiva Cardiocirurgica

²Dipartimento di Scienze Radiologiche,
Azienda Ospedaliero-Universitaria di Parma, Italy

Background: After cardiac surgery, chest radiography (CXR) is usually obtained to evaluate pulmonary complications such as postero-lateral pleural effusion and/or alveolar consolidation (PLAPS), interstitial syndrome (IS), anterior alveolar consolidation (AAC) and pneumothorax (PTX).

Objective: The aim of our study was to evaluate the usefulness of lung ultrasound (LUS) after cardiac surgery to identify pulmonary complications thus obviating the need for a post-procedural CXR.

Patients and methods: Forty-three adult consecutive patients, 33 males and 10 females (mean age 69 ± 10), admitted to the cardiac surgery intensive care unit (ICU) were prospectively included in the study: 24 patients underwent coronary artery bypass grafting and 19 heart valve replacement. On arrival in ICU, lung auscultation, standard CXR and LUS were obtained in all patients. Auscultation and LUS were compared with CXR for their ability to identify pulmonary complications.

Results: According to CXR criteria 19 (45%) patients showed abnormal findings: 6 PLAPS; 6 PLAPS plus IS, 4 IS, 2 AAC and 1 PTX. Compared with CXR, the auscultation had a less diagnostic

accuracy (70%) than LUS (95.3%) for diagnosing any kind of pulmonary complication (Table 1).

Table 1 Sensibility, specificity and diagnostic accuracy of auscultation and LUS for PLAPS, IS, AAC, PTX

	1.1.1.1 Auscultation (%)	1.1.1.2 Lung ultrasound (%)
1.2 PLAPS		
1.2.1 Sensibility	12	100
Specificity	92	90
1.2.2 Diagnostic accuracy	62	93
1.3 IS		
1.3.1 Sensibility	33	100
Specificity	100	100
Diagnostic accuracy	81	100
1.4		
1.5 AAC		
1.5.1 Sensibility	50	50
Specificity	95	98
Diagnostic accuracy	90	95
1.6		
1.7 PTX		
1.7.1 Sensibility	0	100
Specificity	100	100
Diagnostic accuracy	93	100

Conclusion: Our findings showed a higher diagnostic accuracy of LUS in detecting pulmonary complications than auscultation. The systematic use of LUS in ICU may decrease the number of CXR in order of optimize hospital resources utilization and minimize time consumption and radiation exposure.

Abstracts for both 7th Winfocus World Congress and 5th Winfocus Italy Congress

POINT-OF-CARE ULTRASOUND SIMULATION IN A MASS CASUALTY SCENARIO

S. Pappagallo, S. Badiali, L. Calanchi

Emergency Department, AUSL of Bologna, Italy

Background: In mass casualty incidents (MCI) triage is a key-point in order to provide the correct care at the right time: nevertheless, either undertriage or overtriage are commonly observed. Simulations and drills are the most efficient tools for teaching and evaluating MCI management.

Objective: To test if, within a MCI drill, point-of-care ultrasound (US) performed at the secondary triage step can reduce triage errors and improve trauma care.

Patients and methods: An emergency plan for the hospital management of MCI (PEIMAF) was prepared for each of the 9 hospitals of our Department and the involved staff undergo periodic training and evaluation of their ability to manage PEIMAF plan through MCI “stand-up” simulations, according to the Emergo Train System® (ETS) technique and real size drills, using the database of injured patients that comes with the ETS. We implemented the database with US findings by a simple application for tablet or laptop, able to show short US clips for each patient in every expected clinical setting. The application records ATLS measures taken during primary and secondary evaluation, the therapeutic chances after use of US imaging and timing as well. We made this tool available for the first time during a PEIMAF drill in a spoke hospital of ours. The emergency physicians involved were 4, with different curricula on US training and they might ask to use the tool or not.

Results: Only one emergency physician decided to use the US simulator and changed her mind on patient management in every case correctly either by modifying the triage code or by changing care approach with a maximum of 4 min delay.

Conclusion: Although it was only a preliminary test and further data are being collected, it seems that point-of-care US is effective to change patient outcome in MCI situations.

References

1. Farrokhnia N. Emergency department triage scales and their components: a systematic review of the scientific evidence. *Scand J Trauma Resusc Emerg Med.* 2011;19(1):42.
2. Dana S. The history of point-of-care ultrasound use in disaster and mass casualty incidents. *Virtual Mentor.* 2010;12(9):744–9.
3. WHO Guidelines 2007—Mass Casualty Management Systems.

LUNG ULTRASOUND FOR ACUTE DYSPNOEA IN EMERGENCY DEPARTMENT—PRELIMINARY RESULTS

E. Pivetta^{1,2,3}, A. Goffi⁴, E. Lupia⁵, S. Locatelli², A. Rolfo^{2,6}, I. Masi², F. Merletti¹, G. A. Cibinel²

¹Cancer Epidemiology Unit and Piedmont Oncology Prevention Center, AOU S. Giovanni Battista, Turin, and University of Turin

²Emergency Medicine Department, “E. Agnelli” General Hospital, Pinerolo, Turin

³School of Specialisation in Emergency Medicine, University of Turin

⁴Adult Critical Care Department, St. Michael’s Hospital, Toronto, Canada

⁵Emergency Medicine Department, AOU S.Giovanni Battista, Turin, and University of Turin

⁶School of Medicine, AOU San Luigi Gonzaga, Orbassano, and University of Turin

Background: Dyspnoea is a frequent symptom in patients admitted to the Emergency Department (ED), and discriminating between cardiogenic and non-cardiogenic dyspnoea is often a clinical dilemma.

Objectives: The main aim of this study is to evaluate the diagnostic accuracy and impact of LUS, performed by emergency physicians, in identifying the interstitial syndrome and pleural effusion as signs of cardiogenic dyspnea. The study was approved by Ethical Committee of the AOU San Giovanni Battista in Turin.

Patients and methods: The study design is a multicentric prospective cohort, including six EDs in Piedmont, Italy, with a six months recruitment period in each center. The study will recruit 1,000 patients. Adult patients with acute dyspnoea are considered eligible. After the initial diagnostic work-up, the dyspnoea is classified as cardiogenic or respiratory. At this point, LUS and then a chest X-ray are performed. The entire medical records are independently reviewed by a panel of expert physicians blinded to the LUS results, in order to determine if the patient's dyspnoea on presentation was related to heart failure or respiratory disease.

Results: From October 1st, 2010 to March 30th, 2011, 120 patients were enrolled at AOU San Giovanni Battista in Turin and "E. Agnelli" General Hospital in Pinerolo. The median age was 77 years (range 34–99 years). Clinical evaluation had a sensitivity of 91.2% (CI 81.8–96.7) and a specificity of 82.7% (CI 69.7–91.8) for the diagnosis of cardiogenic dyspnoea, with a positive predictive value of 87.3% (CI 77.3–94) and a negative predictive value of 87.8% (CI 75.2–95.4). LUS had a sensitivity of 97.1% (CI 89.8–99.6), a specificity of 92.3% (CI 81.5–97.9), a positive predictive value of 94.3% (CI 86–98.4), and a negative predictive value of 86% (CI 86.3–99.5).

Conclusions: The preliminary results of our study showed a high LUS diagnostic accuracy for the diagnosis of cardiogenic dyspnoea patients admitted to EDs. At the end of enrollement (expected in February, 2012), we will be able to estimate the diagnostic accuracy of LUS in a significantly larger sample of patients.

SYMPTOMATIC UNDIFFERENTIATED HYPOTENSION IN EMERGENCY: THE DIAGNOSTIC USEFULNESS OF A FOCUSED MULTI-ORGAN ULTRASOUND ASSESSMENT

A. Lamorte¹, M. Tullio¹, F. Bar¹, A. Mussa¹, M. T. Giraudo², L. Cardinale³, R. Pozzi⁴, M. F. Frascisco¹, G. Volpicelli¹

¹Department of Emergency Medicine,

³Cardiology Unit,

⁴Radiology Institute, San Luigi Gonzaga University Hospital, Torino, Italy

² Department of Mathematics, University of Torino, Italy

Background: Symptomatic undifferentiated hypotension represents a negative prognostic factor and the strongest predictor of in-hospital mortality. In 76% of cases undifferentiated hypotension remains without any initial diagnostic explanation [1–3]. Misdiagnosis may lead to delayed or incorrect treatment of some life-threatening conditions. The aim of our study is to evaluate the feasibility and accuracy of a new bedside ultrasound method that consists in the focused study of the thorax, abdomen and leg veins, in emergency.

Materials and methods: We prospectively studied hypotensive (<100 mmHg) patients presenting to our emergency department, complaining of at least one of the neurologic, respiratory and cutaneous signs and symptoms of inadequate tissue perfusion. Trauma victims or patients with a clear origin of the condition were excluded. During the first evaluation, each patient was submitted to ultrasound-focused assessment of the heart, lungs, inferior vena cava, peritoneum, aorta and leg deep veins. On the basis of physical examination and sonography, the operator declared the diagnostic hypothesis without influencing the attending physician and the following diagnostic procedure (which included ultrasound, when needed). Diagnostic categories were assigned by using specific sonographic criteria, and were: hypovolaemia (H), distributive (D), cardiogenic (C), obstructive (OC = cardiac tamponade, OE = massive pulmonary embolism, OP = hypertensive pneumothorax), multifactorial

(M), indefinite (I). The diagnostic hypothesis was then compared with the final diagnosis, obtained after the hospital route and discussed by a panel of three experts (one radiologist, one cardiologist and one emergency physician) who considered all the available information but were blinded to the first ultrasound results. The statistical agreement was calculated by the κ of Cohen with p-value, confidence intervals and raw agreement (Ra).

Results: We enrolled 54 patients. Feasibility of the ultrasound study was 100%. The ultrasound diagnoses were as follow: H = 5, D = 17, C = 9, OC = 2, OE = 6, M = 13, I = 2. Out of 54 patients, in 8 cases agreement between the panelists was not possible, and the final diagnosis was undefined. In the remaining 46 patients, the statistic concordance between the clinical and the sonographic diagnoses varied from $\kappa = 0.776$ to $\kappa = 0.943$. The values of κ improved when the groups H and D were considered together and the multifactorial diagnoses were considered concordant if only the main diagnosis was the same.

Conclusion: Preliminary results of this study show that our multi-organ ultrasound method is reliable in the emergency evaluation of non-traumatic undifferentiated hypotension. The first focused sonographic evaluation allows prompt diagnosis and treatment of life-threatening conditions, but cannot replace a second level imaging and other routine tests in the most complicated and multifactorial diagnoses.

References

1. Jones AE, Yiannibas V, Johnson C, et al. Emergency department hypotension predicts sudden unexpected in-hospital mortality: a prospective cohort study. *Chest*. 2006;130(4):941–6.
2. Jones AE, Stiell IG, Nesbitt LP, et al. Nontraumatic out-of-hospital hypotension predicts in-hospital mortality. *Ann Emerg Med*. 2004;43(1):106–13.
3. Jones AE, Aborn LS, Kline JA. Severity of emergency department hypotension predicts adverse hospital outcome. *Shock*. 2004;22(5):410–4.

6th Winfocus World Congress, October 2010

CRITICAL ULTRASOUND APPLICATIONS ON A DOG HIT BY CAR: A CASE REPORT

A. Armenise¹, E. Storti², L. Neri³

¹ Clinica Veterinaria "Santa Fara", Bari (Italy)

² Terapia Intensiva "T. Bozza", A.O. Niguarda Ca' Granda, Milano (Italy)

³ AAT 118 Milano, AREU, A.O. Niguarda Ca' Granda, Milano (Italy)

A 2 years old intact male mixed breed dog was hit by car 1 h prior to presentation. The dog was panting with some fingers wounds. Flow by oxygen was delivered, a venous access was performed for initial treatment with crystalloids solution to correct hypovolemic shock and a blood sample was collected for emergencies laboratory works. A FAST ABCDE-conformed ultrasound assessment showed right pneumothorax and small amount of abdominal free fluid. Thoracocentesis was performed and 500 ml of air was collected. A secondary survey was performed, without any difference with the previous exam. A third survey showed again right pneumothorax, so another thoracocentesis was performed and 30 ml of air were obtained. Two

hours later the dog was rechecked, no pneumothorax or increase of abdominal fluid was found. Subsequent monitoring were unremarkable, without any difference with the previously one.

To the author's knowledge, this is the first reported case of FAST-ABCDE protocol application to a canine trauma patient.

Background: FAST-ABCDE protocol has been developed to establish priorities in the management of human trauma patients, according the critical ultrasound concept, that adapts organ-based comprehensive techniques to problem-based tailored applications. Using this approach, emergency physicians can detect and assess lesions from upper airways (larynx and trachea rupture, dislocation and obstruction), to lungs, pleura and diaphragm (pneumothorax, pleural effusion, pulmonary edema, lung contusions and diaphragmatic injuries), to heart (cardiac dysfunctions, pericardial effusion, volume status), to head (intracranial injuries and hypertension), and finally checking all possible sites for misdiagnosed life-threatening lesions. The protocol gives also the chance to facilitate endotracheal intubation, chest drainage, central venous access, diagnostic peritoneal lavage or paracentesis, urinary catheterization and continuous patient's re-evaluation [1].

In veterinary medicine, abdominal FAST [2] and recently thoracic FAST [3] have been proposed for a rapid diagnosis in traumatized dogs. To our knowledge, FAST-ABCDE has not been yet applied in traumatized dogs.

Objectives: The aim of this report is to evaluate the application of a safe, non invasive and accurate ultrasound protocol, to identify serious life threatening lesions in traumatized dogs.

Methods and materials: The FAST-ABCDE protocol developed for this case report, was modified from FAST-ABCDE established for human use [1], in according with FAST and TFAST modified techniques previously described in dogs [2–4].

The modified protocol consisted in a primary ultrasound evaluation of "Airways" (larynx and trachea), to "Breathing" (right and left 7th–9th intercostal space on the dorsolateral thoracic wall), to "Circulation-Thorax" (4th–6th intercostal space on the ventrolateral thoracic wall, close to the sternum), to "Circulation-Abdomen" (FAST views by subxiphoid region, midline position over the bladder and right and left flank), to Disability (trans-ocular) and to Exposure (miscellanea, re-evaluation).

All scans were performed in both transverse and longitudinal views. Alcohol and acoustic gel were used in all patients. When possible hair was clipped in order to facilitate organs visualization.

The patient was evaluated with an Esaote Mylab 40Vet ultrasound machine (Esaote, Genova Italy), using a multifrequency 5.0–6.6–8.0 MHz micro-convex array probe.

Case report: A 2 years old intact male mixed breed dog was hit by car 1 h prior to presentation. The dog was painting with some fingers wounds. Heart rate was 160 bpm, systolic blood pressure was 120 mmHg. Flow by oxygen was delivered, a venous access was performed for initial treatment with crystalloids solution to correct hypovolemic shock and a blood sample was collected for emergencies laboratory works.

A FAST ABCDE-conformed ultrasound assessment showed right pneumothorax and small amount of abdominal free fluid. A thoracic radiography was performed in order to confirm the diagnosis. Thoracocentesis was performed and 500 ml of air was collected. Laboratory works showed a mild neutrophilia, increase alanine aminotransferase level and a slight decrease of serum potassium.

A secondary survey was performed, without any difference with the previous exam. A third survey showed again right pneumothorax, so another thoracocentesis was performed and 30 ml of air were

obtained. Two hours later the dog was rechecked, no pneumothorax or increase of abdominal fluid was found. Subsequent monitoring were unremarkable, without any difference with the previously one. The dog recovered well, and was discharged from hospitalization 2 days after, with liver enzymes still increased but better than the initial ones.

Conclusions: We present a case in which FAST-ABCDE protocol was applied to a canine trauma patient, allowing to rapidly assess serious life threatening lesions, thus enhancing point-of-care problem solving and decision making.

In veterinary medicine, abdominal and cardiac ultrasound are now widespread at both private and faculty hospitals worldwide, but emergency and critical care ultrasound is relatively a new application available for emergency veterinarians. In fact, only few papers regarding emergency ultrasound are present in veterinary literature. To our knowledge, this report represents the first application of FAST ABCDE ultrasound to an animal patient.

FAST protocol has been introduced in veterinary medicine few years ago when a prospective study demonstrated its high specificity and sensibility to detect abdominal fluids in dog traumatized [2]. Subsequently, an abdominal fluid scoring system has been added to abdominal FAST to better evaluate canine blunt abdominal trauma [4].

Extended FAST protocol has been evaluated for thoracic injuries, looking for pneumothorax, pleural effusion and rib fractures, and showed high specificity and sensibility compared with thoracic radiographs [3].

FAST ABCDE is a new multifocused protocol, designed to assess every compartment, trying to rule in and out life threatening lesions in an accurate and timely fashion. The protocol consists in a total body scan, according and ultrasound pattern recognition and "ABCDE" and "Head-to-toes" conformed approach, with continuous follow up. In this report, particularly, the modified protocol has allowed to detect in the re-evaluation a small closed pneumothorax, excluding other concurrent causes of "Breathing" failure (airway obstruction, hemothorax, diaphragm impairment, massive lung contusion, hypovolemia ...).

We suggest that such a multi-focused protocol should be applied to a large number of canine trauma patients and a retrospective study should be completed, to better understand its clinical role in the management of emergency situations.

References

1. Neri L, Storti E, Lichtenstein D. Toward an ultrasound curriculum for critical care medicine. *Crit Care Med*. 2007;35(5).
2. Boysen SR, Rozanski EA, Tidwell AS, Holm JL, Shaw SP, Rush JE. Evaluation of a focused assessment with sonography for trauma protocol to detect free abdominal fluid in dogs involved in motor vehicle accidents. *J Am Vet Med Assoc*. 2004;225(8): 1198–1204.
3. Lisciandro GR, Lagutichik MS, Mann KA, Voges AK, Fosgate GT, Tiller EG, Cabano NR, Bauer LD, Book BP. Evaluation of a thoracic focused assessment with sonography for trauma (TFAST) protocol to detect pneumothorax and concurrent thoracic injury in 145 traumatized dogs. *J Vet Emer Crit Care*. 2008;18(3):258–269.
4. Lisciandro, Lagutichik MS, Mann KA, Fosgate GT, Tiller EG, Cabano NR, Bauer LD, Book BP, Howard PK. Evaluation of an abdominal fluid scoring system determined using abdominal focused assessment with sonography for trauma in 101 dogs with motor vehicle trauma. *J Vet Emer Crit Care*. 2009;19(5): 426–437.